



Nonfreezing cold water (trench foot) and warm water immersion injuries

Author: Ken Zafren, MD, FAAEM, FACEP, FAWM

Section Editor: Daniel F Danzl, MD

Deputy Editor: Michael Ganetsky, MD

All topics are updated as new evidence becomes available and our [peer review process](#) is complete.

Literature review current through: Mar 2023. | **This topic last updated:** Oct 26, 2022.

Please read the [Disclaimer](#) at the end of this page.

INTRODUCTION

Immersion foot typically refers to an injury caused by cold exposure to tissue not resulting in freezing. This condition is also referred to as trench foot or nonfreezing cold injury (NFCI). NFCI can lead to gangrene or infection acutely, and cold intolerance and pain syndromes chronically.

Although less common, prolonged immersion in warm water can also cause injuries to feet and other tissues. These injuries can be painful and acutely debilitating but typically resolve with basic care and do not have lasting sequelae.

This topic review will discuss the presentation, diagnosis, and management of immersion foot syndromes, specifically NFCI and warm water-related injuries. Hypothermia, frostbite, and other cold-induced injuries are reviewed separately. (See "[Accidental hypothermia in adults](#)" and "[Frostbite: Emergency care and prevention](#)" and "[Pernio \(chilblains\)](#)" and "[Cold urticaria](#)" and "[Overview of cryoglobulins and cryoglobulinemia](#)" and "[Clinical manifestations and diagnosis of Raynaud phenomenon](#)" and "[Disorders of fibrinogen](#)", section on '[Cryofibrinogenemia](#)'.)

TERMINOLOGY AND BACKGROUND

Immersion foot syndromes

Nonfreezing cold injury — NFCI is a general term that includes **trench foot** and its nautical equivalent **immersion foot**. NFCI involves injury to the soft tissues, nerves, and vasculature of distal extremities from prolonged exposure to wet, cold (but nonfreezing; generally 0 to 15°C or 32 to 59°F) conditions. Most often feet are involved, but the condition can affect any dependent body part or the hands. In this topic, we will refer to all such conditions as nonfreezing cold injury (NFCI). Frostbite is distinguished from NFCI because it involves exposure to freezing temperatures, as implied by the name. (See "[Frostbite: Emergency care and prevention](#)".)

Feet and hands that sustain NFCI are initially white and numb ([picture 1](#)), but later become red, edematous, and extremely painful. In severe cases, the extremity can develop hemorrhagic bullae and tissue necrosis. (See '[Nonfreezing cold injury](#)' below.)

The term trench foot was first used during World War I [1], although the condition had been recognized over 100 years earlier during Napoleon's disastrous winter campaign in Russia in 1812 [2]. Immersion foot, an identical injury, was first described during World War II in shipwrecked sailors aboard life boats [3]. When sailors are forced to kneel or sit on the floorboards of a wet boat or the bottom of a lifeboat, the knees or buttocks can be affected. The main civilian groups afflicted with NFCI are shipwrecked crews in cold waters and survivors of wilderness accidents such as plane crashes and capsized boats who must walk in a cold, wet environment with wet shoes and clothing. Hikers and homeless people are also at risk for NFCI.





A number of other conditions either related or identical to NFCI have been described. One likely identical condition is "sea boot foot" or "bridge foot" [4]. This condition was described during World War II in sailors who remained relatively immobile for over four hours at a time while wearing rubber sea boots continuously [5]. The injury has been described in the hand of a diver who was exposed to cold (6°C) water [6].

One related but distinct condition is shelter foot (or shelter limb) [4]. This condition was described during World War II in people who spent nights sitting in cold air-raid shelters without moving or elevating their legs [7]. The severity was worse if the area in or near the popliteal fossa was resting against the cross bar of a deck chair, suggesting that these injuries were peripheral neuropathies.








Warm water immersion injuries

- **Warm water immersion foot (WWIF)** is a transient syndrome first described in soldiers in Vietnam. It manifests as painful, white, wrinkled soles of the feet due to immersion in warm water (15 to 32°C; 59 to 90°F) for up to 72 hours [8]. It has also been called paddy-field foot and, incorrectly and confusingly, "tropical immersion foot," which is a more severe condition [9]. Most patients with WWIF recover completely in one to three days with drying and elevation of the feet [10]. Warm water immersion hand has also been described [11].

As with similar conditions such as frostbite and NCFI, WWIF and measures for its prevention may be forgotten until it recurs. A retrospective survey of a battalion of 400 United States infantry soldiers who trained in rainy mountains in Hawaii in 1994 reported 149 cases of WWIF among the 176 soldiers who returned the questionnaire [12].

- **Tropical immersion foot (TIF)**, also described in soldiers in Vietnam, is a more severe condition than WWIF. TIF causes inability to walk because of painful, swollen feet after immersion in warm water (22 to 32°C; 72 to 90°F) for over 72 hours [10]. TIF is characterized by symmetrical redness, edema, and tenderness of the skin of the ankles and the dorsa of the feet ( picture 2 and  picture 3 and  picture 4 and  picture 5). Treatment includes drying the feet followed by bed rest and elevation of the feet. Complete recovery usually takes four to five days, although severely affected patients sometimes require as long as 10 to 12 days. There are no known sequelae.
- **Jungle foot**, sometimes referred to as "tropical jungle foot," "jungle rot," or "paddy foot," is a poorly defined condition seen in wars in Vietnam. Most, but not all, reports of jungle foot refer to TIF [10].

Other cold-related conditions

- **Frostbite** – Frostbite is a severe, localized, cold-induced injury due to freezing of tissue ( picture 6 and  picture 7). (See "Frostbite: Emergency care and prevention".)
- **Pernio or chilblains** – Pernio, or chilblains, is a condition characterized by localized inflammatory lesions. Chilblains can result from acute or repetitive exposure to cold above the freezing point. In most, but not all, cases, the exposure involves damp cold. Lesions are edematous, often reddish or purple, and may be very painful or pruritic ( picture 8 and  picture 9 and  picture 10 and  picture 11 and  picture 12). (See "Pernio (chilblains)".)

- **Cold urticaria** – Cold urticaria, or cold contact urticaria, is a physical urticaria induced by contact with cold ([🖼️ picture 13](#)). Cold urticaria is characterized by hives or angioedema. (See "[Cold urticaria](#)".)
- **Cryoprecipitation** – Cryoprecipitation refers to precipitation of blood proteins at temperatures below 37°C. There are two types of cryoprecipitation: cryoglobulinemia and cryofibrinogenemia. Cryoglobulinemia refers to precipitation of blood proteins from serum and plasma. People with cryoglobulinemia are asymptomatic, but some may develop hyperviscosity or thrombosis. Cryofibrinogenemia refers to precipitation of proteins from plasma. Most people with cryofibrinogenemia are asymptomatic, but some may develop thrombosis. (See "[Overview of cryoglobulins and cryoglobulinemia](#)" and "[Disorders of fibrinogen](#)", section on 'Cryofibrinogenemia'.)
- **Raynaud phenomenon** – Raynaud phenomenon is an exaggerated vascular response to cold temperature or emotional stress characterized by well-demarcated pallor, cyanosis, or both of the distal parts of digits ([🖼️ picture 14](#)). (See "[Clinical manifestations and diagnosis of Raynaud phenomenon](#)".)

EPIDEMIOLOGY OF NONFREEZING COLD INJURY

Individuals are at risk for nonfreezing cold injury (NFCI) if the extremities are cold and wet for prolonged periods of time, usually two to three days or longer [1,13]. However, NFCI has been reported after immersion in cold sea water (0 to 8°C; 32 to 46°F) after only 14 to 22 hours [5]. Most victims of NFCI are exposed to cold ambient conditions and subjected to fatigue, malnutrition, and restricted movement, while being forced to wear shoes or boots continuously for many days.

Some authors have concluded that neither cold nor wet are necessary to produce NFCI [14]. There are also claims that temperatures as high as 20°C or exposures less than one hour can cause NFCI [15]. None of these assertions are substantiated by the literature.

- **Military** — Most cases of NFCI occur in military settings, both during combat operations and during training. American forces reported 11,000 cases of trench foot during November 1944 in World War II [14]. During the Falklands conflict of 1982, infantry units in one United Kingdom brigade reported an incidence of 76 percent [14].
- **Civilian** — Hikers and others who are exposed to cold, wet conditions for days without removing wet boots and socks are at risk for NFCI. Other high-risk groups are homeless

people, alcoholics, and older adults.

- **Demographics** — Although historical reports describe particular populations as being more susceptible to NFCI, the reliability of such reports is uncertain [5,16]. There is no clear evidence that specific groups are at increased or decreased risk.
-

PHYSIOLOGY

- **Thermoregulatory function of skin** — The most important physiologic function of skin is thermoregulation. Skin blood flow is under both central and local control. In cold conditions, vasoconstriction can decrease skin blood flow to approximately 10 percent of baseline values. Because the metabolic demands of skin are low, decreased blood flow alone does not cause ischemia. Skin blood flow can also be decreased during periods of immobility when limbs are below the level of the heart.
 - **Cold-induced vasodilation** — Maximal vasoconstriction occurs when a hand or foot is cooled to approximately 15°C (59°F). Further cooling causes increases in blood flow known as cold-induced vasodilation (CIVD) or the "hunting response." CIVD occurs in 5- to 10-minute cycles. Prolonged and repeated cold exposures increase the amplitude and frequency of CIVD. Inuits, Sami people, and Nordic fisherman have large CIVD response with rapid cycling [17]. A strong CIVD response is thought to decrease susceptibility to NFCI, but scientific evidence is lacking. A study of 206 Dutch Marines has been characterized as showing that a weak CIVD response correlates with increased susceptibility to NFCI [18]. However, in the 11 subjects who later sustained cold injury, the injury was frostbite rather than NFCI.
-

PATHOPHYSIOLOGY OF NONFREEZING COLD INJURY

Nonfreezing cold injury (NFCI) is characterized by impaired control of circulation and direct damage to the microcirculation, but the mechanism is poorly understood. In animal studies, vascular damage includes microvascular thrombosis with endothelial damage. Reperfusion injury likely plays a role. Animal studies suggest that there can be reversible or permanent damage to nerves from cold, as well as damage to the microvascular blood supply of the nerves. The mechanism of direct neural damage is supported by clinical case reports of reversible peripheral nerve damage in people with severe hypothermia [19,20].

Although many authors attribute NFCI solely to prolonged vasoconstriction [14,15], the

cause is likely more complex [21]. Animal experiments suggest that tissue damage is inversely proportional to tissue temperature and directly proportional to duration of exposure but that repeated exposure is likely to cause more damage than a single, longer exposure [14,15]. The duration of a single exposure at a given temperature that is necessary to cause NFCI is not known, nor are there quantitative estimates of the effects of repeated exposure. Cold alone, without moisture, does not seem to be sufficient to cause NFCI. Immobility and malnutrition appear to contribute to injury in many cases.

Tissue loss is generally not a feature of NFCI. Tissue loss in severe cases of NFCI is likely caused by pressure injury with or without compartment syndrome when boots become tight after the feet swell, rather than cold. Mechanical damage to the tissue also seems to contribute to tissue loss, such as in circumstances in which victims of NFCI must walk for long distances with wet, swollen feet.

PATHOPHYSIOLOGY OF WARM WATER IMMERSION INJURY

Research into the pathophysiology of warm water immersion injuries is limited. Warm water immersion foot (WWIF) is thought to be caused by hyperhydration (waterlogging) of the plantar stratum corneum when continuously exposed to warm water for up to 72 hours [10]. Tropical immersion foot (TIF) appears to be caused by the passage of water through compromised epidermis into the dermis when the feet are continuously exposed to warm water for longer than 72 hours [10].

RISK FACTORS FOR NONFREEZING COLD INJURY

Risk of nonfreezing cold injury (NFCI) exists with exposure to wet cold at temperatures from 0°C (and also slightly below freezing) to approximately 15°C (59°F) [5]. During World War II, prolonged exposure of shipwrecked sailors to sea water at estimated temperatures of 16 to 21°C (61 to 70°F) for eight days resulted in injuries similar, if not identical, to immersion foot [16].

There is great variability among individuals in susceptibility to cold injury. Nevertheless, some common risk factors have been identified. Situational factors that contribute to NFCI include immobility, inadequate or wet clothing, constricting boots and clothing, inadequate fluid or caloric intake, and fatigue and stress, especially in combat. Associated injuries or underlying circulatory problems, including peripheral vascular disease or Raynaud

phenomenon, may contribute to the risk or severity of NFCI. Diabetes causes circulatory problems that may predispose to NFCI. Smoking, older age, and ethnicity may play a role, but data are lacking. Mental illness and alcohol use are also likely risk factors.



A study of 100 soldiers referred to a military clinic in the United Kingdom with suspected NFCI reported that 76 were diagnosed with the condition while 24 received alternate diagnoses, most commonly neurapraxia and Raynaud's phenomenon [22]. The authors concluded that NFCI occurs most often during winter training in younger, less-experienced personnel. Risk factors included African-Caribbean ethnicity (higher risk than White individuals), "feeling generally cold," performing static duties, wearing wet boots and clothing, and immersion of the affected limb in water.

RISK FACTORS FOR WARM WATER IMMERSION INJURY

The main risk factor for warm water immersion foot (WWIF) and tropical immersion foot (TIF) is continuous exposure of the feet to water at or above 15°C (59°F) without an opportunity for drying [10]. Heavy callouses predispose to WWIF [10]. Previous episodes of TIF increase the risk of recurrence [10].

CLINICAL MANIFESTATIONS

Nonfreezing cold injury — Historical features most closely associated with the diagnosis nonfreezing cold injury (NFCI) include an extremity that lost feeling for over 30 minutes and painful rewarming or rewarming with abnormal sensation [23]. Extremities with NFCI progress through a series of "stages" [5,15]. The duration of each stage varies considerably among patients. Transitions between stages may be abrupt or gradual.

- **First stage: During cold exposure** — The key finding in the first stage is loss of sensation. This usually takes the form of complete anesthesia. Patients complain of "numbness," sometimes describing feet or hands as feeling like a block of wood. Due to this loss of sensation and proprioception, patients may become clumsy and may have difficulty walking. Extremities may be bright red at first but then become pale or completely white due to extreme vasoconstriction ( picture 1 and  picture 15). The extremity is usually painless unless rewarming is attempted.
- **Second stage: Following cold exposure** — The second stage begins as soon as the patient is removed from the cold environment and continues during and after

rewarming. This stage usually lasts just a few hours but may persist for as long as several days. The extremities become a mottled pale blue, reflecting a slight increase in blood flow. The color change can be hard to see in darkly pigmented skin. Peripheral pulses are initially thready. Subsequently, pulses become bounding, but capillary refill is delayed. The extremity continues to be cold and numb. Some swelling can occur. The patient may still have problems walking.

- **Third stage: Hyperemia** — The third stage typically begins abruptly and lasts for days to weeks, in severe cases, for 6 to 10 weeks. The affected extremity becomes bright red and edematous with bounding pulses but with delayed capillary refill, reflecting microcirculatory damage. Anesthesia is replaced by intense pain with hyperalgesia. However, the distal areas of the affected extremities may remain anesthetic. Tissue damage is usually not apparent, but highly damaged areas may develop blistering. Nonviable areas of tissue are rare but may become blistered or discolored before developing necrosis in the fourth stage.
- **Fourth stage: Following hyperemia** — The fourth and final stage may end after a few weeks, persist for years, or be permanent. The affected extremity usually appears normal, unless there has been tissue necrosis, which is uncommon. Affected extremities are cool and are often very sensitive to cold. Vasoconstriction in response to cold is common. Extremities may remain cool for hours after a brief exposure to cold. The majority of patients have chronic pain, usually in response to cold. Small areas may continue to be anesthetic. Hyperhidrosis (excessive sweating) is common. Some patients develop symptoms similar to complex regional pain syndrome (CRPS), if not actually CRPS. In severe cases, tissue necrosis can occur, necessitating amputation. (See ["Complex regional pain syndrome in adults: Pathogenesis, clinical manifestations, and diagnosis"](#).)

Warm water immersion injuries — There are two major types of warm water immersion injuries: warm water immersion foot (WWIF) and tropical immersion foot (TIF).

WWIF manifests as painful, white, wrinkled soles of the feet caused by immersion in warm water (15 to 32°C) for up to 72 hours [10]. Symptoms include pain on weight-bearing and abnormal sensations in the feet, such as tingling or feeling like one is "walking on rope" [10].

TIF is a more severe injury that develops when feet are wet continuously in warm water (22 to 32°C) for three days or longer [10]. The first symptom is a burning sensation that is more severe on the dorsal surfaces than on the soles. Walking becomes increasingly painful. When

the victim removes their shoes (usually combat boots) to examine the feet, the feet are typically too swollen to replace the footwear [10]. At hospital admission, the feet are bright red with a line of demarcation at boot-top level, with pitting dorsal and ankle edema ([picture 3](#) and [picture 4](#) and [picture 5](#) and [picture 2](#)). The skin is cool initially but becomes warm within 12 hours. Pulses are full and capillary refill is brisk. Fever and inguinal lymphadenopathy without lymphangitis may be found in severe cases [10].

Abrasions from wet socks and ulcerations over pressure points, where footwear puts pressure on swollen tissue of the feet or ankles, are common. Typically, these lesions develop over areas of swollen tissue rather than over bony prominences.

Plantar surfaces are hyperhydrated and wrinkled. In Vietnam in the mid-1960s, patients with severe cases had fever and inguinal lymphadenopathy. These findings were not present in the original descriptions from World War II in the South Pacific. Recovery begins with resolution of fever and adenopathy, decreased pain and tenderness, and normalization of the plantar surfaces within two to three days. The redness of the dorsal surfaces and ankles resolves, changing to diffuse blotchy ecchymosis, tiny vesicles, and a fine maculopapular rash. Edema resolves in four to seven days. Following desquamation, the skin becomes normal without vasomotor changes.

DIAGNOSIS

Nonfreezing cold injury — Nonfreezing cold injury (NFCI) may (rarely) coexist with frostbite, complicating the diagnosis. If there was no exposure to temperatures several degrees below freezing, frostbite can be ruled out. Diagnosis of NFCI depends on a history of prolonged exposure to cold (generally slightly below 0 to 15°C), wet conditions, and clinical findings consistent with the four stages of injury described above. The primary alternative diagnosis is frostbite. Frostbite that has been thawed may become hyperemic and swollen within hours, but a sharp demarcation between distal affected and proximal unaffected tissue distinguishes frostbite from NFCI. (See '[Clinical manifestations](#)' above and "[Frostbite: Emergency care and prevention](#)".)

Warm water immersion injury — In most cases, the history and examination findings alone are sufficient to diagnose warm water immersion foot (WWIF) or tropical immersion foot (TIF).

- **WWIF** presents after immersion in warm water (15 to 32°C) up to 72 hours. The feet are painful with white, wrinkled soles and possibly mild swelling.

- **TIF** occurs from longer exposure and manifests initially as burning pain, pain with walking, and symmetrically swollen, red, tender feet and ankles, typically with a clear line of demarcation at the level of the boot tops. Pain is increased by weight-bearing. The skin is initially cool but becomes warm within 12 hours. Wet-sock abrasion and small ulcerations over pressure points, where the footwear puts pressure on swollen tissue of the feet or ankles, are common. In severe cases, fever (38 to 39°C) and inguinal lymphadenopathy without lymphangitis may be present [10].

DIFFERENTIAL DIAGNOSIS OF NONFREEZING COLD INJURY

Frostbite — Although frostbite can be confused with nonfreezing cold injury (NFCI), a history of exposure to temperatures well below freezing favors frostbite, especially if there has been direct exposure of digits to subfreezing cold air. Nevertheless, frostbite and NFCI can conceivably coexist, making diagnosis difficult. Like NFCI, frostbite can initially have a pale appearance. However, unlike tissue with NFCI, frostbitten tissue that is still frozen appears waxy and feels firm.

After thawing, frostbitten hands or feet can become hyperemic and swollen. Unlike NFCI, frostbitten tissue becomes cyanotic after thawing with a demarcation between affected and unaffected tissue of the digits, hands, or feet. Formation of blisters in the first 24 hours can occur in frostbite but is rare in NFCI. Blisters that occur in the initial course of NFCI are caused by pressure-induced injury. (See "[Frostbite: Emergency care and prevention](#)".)

Pressure-induced injury and acute compartment syndrome — Pressure-induced soft tissue injury and acute compartment syndrome (ACS) result from elevated tissue pressures that compromise blood flow leading to severe pain and, in ACS, local and possibly distal ischemia. If there is exposure to wet, cold conditions, these conditions may coexist with and complicate NFCI. Tissue necrosis occurring in dry conditions is more commonly caused by pressure-induced injury, ACS, or a combination of the two, even in the setting of cold exposure.

A history of immobility without cold exposure or the presence of typical pressure sores over bony prominences suggests isolated pressure-induced injury. Pressure-related ulcerations associated with immersion foot develop when footwear restricts further swelling and places pressure on soft tissues that are already swollen. Lesions generally occur on soft tissues rather than bony prominences.

ACS most often develops following significant trauma (eg, long bone fracture) but may occur

from ischemia-reperfusion injury. Important findings with ACS include progressive pain out of proportion to the injury accompanied by tense, swollen compartments. ACS is a surgical emergency diagnosed by measuring elevated compartment pressures and treated with fasciotomy. (See "[Acute compartment syndrome of the extremities](#)".)

Imaging is helpful in identifying fractures but not in distinguishing pressure-induced injury from NFCI. Whether or not there is exposure to cold conditions, soft tissue infection can complicate pressure injury or ACS.

Soft tissue infection — In wet, cold conditions, soft tissue infection can complicate NFCI. In dry, cold conditions, soft tissue infection can be mistaken for NFCI. Distinguishing soft tissue infection from NFCI may be difficult. The presence of fever or other systemic symptoms such as nausea suggests infection, but low-grade fever can occur during the first few days of NFCI alone [24]. Lesions from NFCI are often symmetric, unlike infections. Imaging studies may reveal an abscess. However, imaging cannot distinguish inflammation due to infection without abscess from inflammation due to NFCI. A bedside ultrasound examination may be useful if a secondary loculation suggests an abscess.

DIFFERENTIAL DIAGNOSIS OF WARM WATER IMMERSION INJURY

NFCI or frostbite — Lesions from warm water immersion injury may resemble those from nonfreezing cold injury (NFCI) or frostbite. NFCI or frostbite can usually be distinguished from warm water immersion foot (WWIF) or tropical immersion foot (TIF) based on whether there is a history of exposure to cold or warm water.

Pressure-induced soft tissue injury — Pressure-induced soft tissue injury can lead to blistering or ulceration, both of which may be rare sequelae of warm water immersion injury, although small ulcerations can develop over pressure points—sites where footwear constricts soft tissue swelling. Typically, this occurs over areas where tissue is already swollen to some extent, rather than over bony prominences [10]. Pressure-induced injury may coexist with warm water injury.

Soft tissue infection — TIF causes symmetrical erythema, edema, and tenderness at the ankles and dorsa of the feet and, in severe cases, may cause fever and inguinal lymphadenopathy. While soft tissue infections may cause similar symptoms and signs, they are highly unlikely to present with symmetrical findings. Bacterial infections and dermatophytoses are more common than TIF after exposure to warm wet conditions for three or more days [10]. Streptococcal cellulitis is usually unilateral and associated with

painful swelling of the leg [10]. Dermatophytosis occurs in patches and confluent areas, unlike TIF which is diffuse and symmetrical [10]. (See "[Dermatophyte \(tinea\) infections](#)" and "[Cellulitis and skin abscess: Epidemiology, microbiology, clinical manifestations, and diagnosis](#)".)

Wet-sock erosions — Wet sock erosions are superficial erosions of the skin that are limited to areas of friction and pressure, especially areas under bootlaces, unlike the lesions of TIF that cover the dorsum and ankle [10].

MANAGEMENT OF NONFREEZING COLD INJURY

Prehospital care — Get the patient to a warm environment as soon as possible. Treat systemic hypothermia before treating local cold injury (frostbite or nonfreezing cold injury [NFCI]). (See "[Accidental hypothermia in adults](#)", section on 'Management'.)

If rescued in the prehyperemic stage, the patient should be carried and not allowed to walk if possible [5]. A vapor barrier, insulated wrap should be put over wet clothing initially to prevent or limit hypothermia. Remove wet clothing only after the patient is sheltered.

Treat frostbite, if present, before treating NFCI. The treatment of frostbite is discussed in detail separately (see "[Frostbite: Emergency care and prevention](#)"). Do not rewarm an extremity affected by NFCI unless frostbite is also present and portions of the extremity are still frozen. Affected limbs should never be rubbed.

Emergency department management — Treat systemic hypothermia by rewarming. Do not actively rewarm extremities with isolated NFCI. Examine the patient closely for other conditions and injuries. (See "[Accidental hypothermia in adults](#)", section on 'Management'.)

Replace fluid losses, which may be substantial. Use isotonic intravenous fluids warmed to 42°C to both rehydrate and prevent hypothermia.

Extremities with NFCI should be allowed to rewarm gradually with bed rest, elevation of the legs or hands, and air drying at room temperature [25]. Rapid rewarming increases pain and edema and is thought to increase the metabolic demands of injured skin [5]. Analgesia is discussed below. (See '[Inpatient management](#)' below.)

Tetanus prophylaxis is recommended. There is no role for prophylactic antibiotics in the treatment of isolated NFCI. (See "[Infectious complications of puncture wounds](#)", section on '[Tetanus immunization](#)'.)

Inpatient management — Continue any necessary emergency treatment (eg, rewarming, rehydration). Affected limbs should be elevated above the level of the heart and protected from constriction or mechanical damage (eg, cushions below feet). Affected limbs should be kept open to air or lightly and loosely dressed.

During the prehyperemic stage, the extremity is numb. Once the hyperemic stage begins, it is necessary to control pain. Prophylactic treatment of pain prior to the hyperemic stage is ineffective. The clinical stages of NFCI are described above. (See '[Nonfreezing cold injury](#)' above.)

Cooling of the feet using a fan in a cool room (15 to 18°C) may be helpful to relieve pain during the hyperemic stage [5]. This can be accomplished by putting a small fan on a bedside table and aiming it at the feet [5]. Early authors described lowering the temperature of the feet using ice bags with the feet wrapped in sterile towels [24]. This seemed to be effective in relieving swelling and pain, but we recommend against this treatment because it risks worsening the injury.

Nonsteroidal antiinflammatory drugs (NSAIDs) and opioids may be administered initially for pain relief but are usually ineffective. Vasodilators, such as [nifedipine](#), have not been shown to be helpful [15]. Lumbar sympathectomy (regional anesthesia) is obsolete and should not be performed. Although it sometimes alleviates cold sensitivity for a few months, after treatment, symptoms return at least as severe as before treatment (and sometimes worse) [14,15].

[Amitriptyline](#) 50 to 100 mg orally at bedtime has been a standard treatment for pain in the United Kingdom armed forces since 1982 [15]. Higher doses can be given for breakthrough pain. We recommend starting amitriptyline early in the treatment course (ie, as soon as pain develops) [26,27]. If amitriptyline is not effective, neuropathic pain medications such as [gabapentin](#) can be administered. There are no published clinical trials of regimens for pain control in patients with immersion injuries.

Low-grade fever is common in the first 12 to 36 hours. It generally resolves without treatment [24].

If cellulitis develops, antibiotic treatment should be given to cover staphylococci, streptococci, and pseudomonas species. Prophylactic antibiotics are not indicated. (See "[Cellulitis and skin abscess: Epidemiology, microbiology, clinical manifestations, and diagnosis](#)" and "[Acute cellulitis and erysipelas in adults: Treatment](#)".)

We recommend obtaining urgent surgical consultation for any sign of possible tissue necrosis, such as hemorrhagic blistering. (See "[Necrotizing soft tissue infections](#)" and "[Surgical management of necrotizing soft tissue infections](#)".)

General care of the patient traditionally includes a high-protein diet and prohibition of smoking.

Diagnostic studies — NFCI is a clinical diagnosis; no specific imaging or laboratory studies are useful for establishing the diagnosis. Furthermore, imaging or laboratory studies are generally unnecessary in uncomplicated cases. The presentation of the patient and the development of complications determine the need for diagnostic studies.

Plain radiographs of the affected hands or feet should be obtained if traumatic injury is suspected. If infection is suspected, computed tomography (CT) or magnetic resonance imaging (MRI) should be obtained to look for free air, abscess, or other findings that would mandate surgical intervention. Early surgical consultation is advisable if soft tissue infection is suspected.

Unlike frostbite, there is no known role for angiography, CT angiography (CTA), magnetic resonance angiography (MRA), or radioisotope scanning in the evaluation of NFCI.

Infrared thermography is not indicated in the acutely injured. Infrared thermography was once used in the United Kingdom to assess injury severity and recovery but has been abandoned as it was not validated in controlled trials [14].

Follow-up care — In recent decades, the majority of United Kingdom soldiers have been diagnosed with mild nonfreezing cold injury, but many do not meet the criteria we use for diagnosis of NFCI. Nevertheless, the care regimen following hospital discharge developed by the United Kingdom military provides a reasonable approach:

- Soldiers with minimal symptoms are allowed to work outdoors if they can stay warm enough to prevent numbness.
- Soldiers with peripheral neuropathy are referred for further evaluation, including an intraepidermal nerve fiber density study.
- Soldiers with persistent pain are referred for pain management.
- Some soldiers who become asymptomatic without physical findings on examination are gradually introduced to progressively colder environments. If they have normal

responses to cold, without cold sensitivity, they can return to full duty.

Sequelae of NFCI may include persistent neuropathic pain and complex regional pain syndrome (CRPS). Referral to a pain management clinic is indicated if pain persists (see ["Complex regional pain syndrome in adults: Treatment, prognosis, and prevention"](#)). Physical and occupational therapy may be helpful for regaining function.

We do not use [iloprost](#), a prostaglandin I₂ analog, for treating the sequelae of NFCI. A case report describes the use of iloprost to treat a 41-year-old military veteran with foot pain and decreased mobility 20 years after NFCI [28]. After a five-day infusion of iloprost, he enjoyed four weeks of decreased pain and increased mobility but gradually relapsed over several weeks. A second infusion three months later caused increased pain, which subsided to baseline over the following months.

MANAGEMENT OF WARM WATER IMMERSION INJURY

Warm water immersion foot (WWIF) resolves in two to three days if the feet are kept dry [10]. Treatment of tropical immersion foot (TIF) consists of drying the feet, followed by bed rest and elevation of the feet. Complete recovery including resolution of edema usually takes four to five days, although severely affected patients sometimes require as long as 10 to 12 days. Following desquamation, the skin becomes normal without vasomotor changes. There are no known long-term sequelae.

Prophylactic antibiotics are not indicated for the treatment of WWIF or TIF. Associated infections can be treated with topical antifungal agents for dermatophytoses or systemic antibiotics for bacterial cellulitis or deeper infection. (See ["Dermatophyte \(tinea\) infections"](#) and ["Cellulitis and skin abscess: Epidemiology, microbiology, clinical manifestations, and diagnosis"](#) and ["Acute cellulitis and erysipelas in adults: Treatment"](#).)

[Amlodipine](#) [15] and medications that treat neuropathic pain, such as [gabapentin](#) [26,27], may be effective for analgesia during recovery.

COMPLICATIONS OF NONFREEZING COLD INJURY

Short-term complications of nonfreezing cold injury (NFCI) can include gangrene and infection of the affected area. When patients begin walking again, they often have a "slapping, flat-footed, springless gait" that improves in approximately a week [24]. Chronic

pain and temperature sensitivity are among potential longer term complications.

The third stage of NFCI begins hours to a few days after removal from the cold environment. (The stages of NFCI are described above (see '[Nonfreezing cold injury](#)' above).) During this stage, severe pain with allodynia (hyperalgesia to light touch) develops, even in the absence of obvious tissue damage [15]. Pain is often worse at night. Conventional analgesics, including nonsteroidal antiinflammatory drugs (NSAIDs) and opioids, are usually ineffective. [Amitriptyline](#), 50 to 100 mg given orally at bedtime, has been a standard treatment for pain in the United Kingdom armed forces since 1982 [15]. Higher doses can be given for breakthrough pain. Some centers start drugs to treat neuropathic pain early in the course of treatment [26,27]. Medications such as [gabapentin](#) may be effective. There are no published clinical trials of regimens for pain control in patients with NFCI.

The fourth stage of NFCI, following hyperemia, lasts for weeks to years. Long-term complications are due primarily to peripheral neurovascular injury, with associated abnormalities of sympathetic tone [15,29]. The severity of complications generally correlates with the severity of the original injury. The sequelae of NFCIs are similar but often more debilitating than those produced by frostbite. (See "[Frostbite: Emergency care and prevention](#)", section on '[Complications](#)'.)

Areas affected by NFCI often feel cold and experience prolonged episodes of vasoconstriction, especially after re-exposure to cold [2]. In addition, re-exposure to cold commonly causes pain [24]. Two small studies of soldiers with painful sequelae from NFCI identified a number of abnormalities in nerve and skin tissue and concluded that pain was due to sensory neuropathy or "vaso-neuropathy" [30,31]. These complications are likely to be permanent except in mild cases. Pain may be provoked by walking [24]. Scaling ulceration and nail loss can occur intermittently without any obvious provoking injury or exposure. Patients with persistent pain and allodynia may develop complex regional pain syndrome (CRPS). (See "[Complex regional pain syndrome in adults: Pathogenesis, clinical manifestations, and diagnosis](#)" and "[Complex regional pain syndrome in adults: Treatment, prognosis, and prevention](#)".)

The descriptions above are born out in a case series of 76 patients diagnosed with NFCI [23]. In six of the patients, symptoms resolved within a week of injury, but among patients seen in clinic a few months later, three-quarters complained that the affected extremity cooled more easily and had "abnormal sensation" when it was cold, while just over two-thirds reported that rewarming from the cold was painful. When the extremity was not cold, about one-third of patients continued to have "abnormal sensations," including paresthesias, and almost half

had abnormal thermal sensation when touching things that were hot or cold. The most common clinical finding was "abnormal pinprick sensation," which was present in nearly 90 percent of patients.

Chronic pain can vary depending on the circumstances of the original injury. The author has examined a patient who had to stand in cold water on a regular basis during combat. He subsequently developed severe arthropathy of all major joints below the shoulders, with the exception of the elbow on the arm he used to keep his rifle above water.

Military personnel may not be able to redeploy after NFCI, especially not to cold environments [15]. Severely affected individuals may be unable to work outdoors [14]. NFCI was a career-ending injury for 25 of 42 soldiers referred to a United Kingdom pain clinic for sequelae of NFCI [30]. The remaining personnel were downgraded to limit exposure to cold environments. Of the soldiers who were discharged, over half were unemployed at least partly due to needing to work in warm environments.

Although severe sequelae may be common, those with milder cases of NFCI generally recover. A study of 26 Norwegian soldiers with NFCI found that only seven developed chronic cold hypersensitivity [32]. At two months after injury, 19 had numbness of the feet, 16 had cold hypersensitivity, and 7 were asymptomatic.

Hyperhidrosis is common and may lead to recurrent paronychia fungal infections. Nails may become thick and deformed. Sweating can be provoked by cold or heat or by emotional stimuli [15]. In some cases, persistent, mild sensitivity to cold can be tolerable, but alternating pain and paresthesias, Raynaud syndrome, swelling, and chronic fungal infections may develop after many years [15]. (See "[Paronychia](#)".)

Psychiatric sequelae associated with chronic, poorly relieved pain can include depression with suicidal thoughts and alcohol or substance abuse. (See "[Evaluation of chronic non-cancer pain in adults](#)", section on '[Psychiatric comorbidity](#)'.)

COMPLICATIONS OF WARM WATER IMMERSION INJURY

The most common complication of warm water immersion injuries appears to be fungal infection [8]. Bacterial infections are also possible. Neither warm water immersion foot (WWIF) nor tropical immersion foot (TIF) has known long-term sequelae. (See "[Dermatophyte \(tinea\) infections](#)", section on '[Tinea pedis](#)'.)

PREVENTION OF NONFREEZING COLD INJURY

There is a paucity of evidence regarding measures to help prevent nonfreezing cold injury (NFCI). Many specific recommendations are based on prevention of other injuries. As one example, recommendations to air-dry feet for at least 8 of every 24 hours are based on studies of warm water immersion foot (WWIF) [25,33], while suggestions to dry feet for 24 hours after every 48 hours of immersion has been suggested for tropical immersion foot (TIF) [34].

Trench foot was virtually eliminated among Allied forces along the Western Front during World War I when rations were increased and waterproof bags of clean, dry socks were sent nightly to the trenches along with the rations [13]. Prohibitions against applying puttees (wraps around the lower leg above the boots that caused constriction) and encouraging soldiers to move around as much as they could contributed to lower rates, as did the use of gum boots and foot powder rather than oils.

Measures that may be used to reduce the risk of developing NFCI include the following:

- **Avoid cold/wet conditions.**

If it is not possible to avoid cold, wet conditions, limit exposure as much as possible. In military settings, avoid re-exposing casualties who have previously sustained NFCI, especially if they are sensitized to cold.

- **Wear clothing that provides thermal protection but is not constricting. Change socks regularly.**

This is especially important for foot gear. Feet should be kept as dry as possible. Vapor barrier boots can be effective in retaining warmth and avoiding wet feet but can become wet from within. Foot care should include changing into dry socks two or three times daily in high-risk conditions.

- **Stay active.**

Movement is important to maintain adequate circulation in the extremities. Avoid prolonged dependency of the feet.

- **Avoid malnutrition, dehydration, and fatigue.**

Especially in military settings, recognize that stress can cause vasoconstriction. Education

and training for cold weather operations may help to avoid stress. Regular rotation of personnel out of cold-exposure environments is the most effective measure against NFCI [2]. The optimum timing and duration of removal from a cold environment is not known.

Use of grease or oils is not helpful and is likely harmful [13].

PREVENTION OF WARM WATER IMMERSION INJURY

The main method of preventing warm water immersion foot (WWIF) is to allow the feet to dry every night after prolonged exposure to warm water [8]. Daily application of silicone grease to the soles of the feet, between the toes, and up to the level of the malleoli is effective for preventing WWIF if nightly drying is not feasible [8]. There is no additional benefit to using silicone on the entire foot [35].

Prevention of tropical immersion foot (TIF) involves limiting exposure to water by keeping the feet dry for 24 hours after every 48 to 72 hour period of constant exposure to water [10].

SOCIETY GUIDELINE LINKS

Links to society and government-sponsored guidelines from selected countries and regions around the world are provided separately. (See "[Society guideline links: Management of environmental emergencies](#)".)

SUMMARY AND RECOMMENDATIONS

- **Terminology, epidemiology, and risk** – Nonfreezing cold injury (NFCI) is a general term that includes trench foot and immersion foot. NFCI involves injury to the soft tissues, nerves, and vasculature of distal extremities from prolonged exposure (usually two to three days or longer) to wet, cold (but nonfreezing; generally 0 to 15°C or 32 to 59°F) conditions. Most often feet are involved ([picture 1](#)), but the condition can affect any dependent body part. NFCI has been reported most often in combat soldiers, but other populations at risk include hikers, the homeless, heavy alcohol users, and older adults. (See '[Terminology and background](#)' above and '[Epidemiology of nonfreezing cold injury](#)' above.)

Warm water immersion foot (WWIF) is a transient syndrome that manifests as painful, white, wrinkled soles of the feet due to immersion in warm water (15 to 32°C; 59 to

90°F) for up to 72 hours. Tropical immersion foot (TIF) is a more severe warm water immersion syndrome characterized by an inability to walk due to painful, swollen feet after immersion in warm water (22 to 32°C; 72 to 90°F) for over 72 hours ([picture 2](#) and [picture 3](#) and [picture 4](#) and [picture 5](#)). (See 'Terminology and background' above and 'Warm water immersion injuries' above.)

- **Pathophysiology and clinical presentation** – NFCI is characterized by impaired control of circulation and direct damage to the microcirculation, but the mechanism of cold and warm water immersion syndromes is poorly understood. The duration of a single exposure at a given temperature necessary to cause NFCI is not known, nor are there quantitative estimates of the effects of repeated exposure. Cold alone, without moisture, does not seem to be sufficient to cause NFCI. Immobility and malnutrition contribute to injury in many cases. (See 'Pathophysiology of nonfreezing cold injury' above and 'Pathophysiology of warm water immersion injury' above and 'Physiology' above.)

Extremities with NFCI progress through a series of stages that can vary considerably in duration (see 'Nonfreezing cold injury' above):

- **First stage: During cold exposure** – Loss of sensation, usually complete anesthesia, is the key finding. Patients complain of "numbness." Due to diminished sensation and proprioception, patients may have difficulty walking. Extremities may be bright red at first but then become pale or completely white ([picture 1](#)). The extremity is usually painless.
- **Second stage: Following cold exposure** – This stage begins as soon as the patient is removed from the cold and continues during and after rewarming, usually lasting a few hours but possibly several days. Affected extremities become a mottled pale blue, reflecting a slight increase in blood flow (may be hard to see in darkly pigmented skin). Peripheral pulses are initially thready; subsequently, pulses become bounding, but capillary refill is delayed. The extremities continue to be cold and numb. Difficulty walking may persist.
- **Third stage: Hyperemia** – This stage typically begins abruptly and lasts for days to weeks. The affected extremity becomes bright red and edematous with bounding pulses but delayed capillary refill. Anesthesia is replaced by intense pain with hyperalgesia. Tissue damage is usually not apparent.
- **Fourth stage: Following hyperemia** – This stage may end after a few weeks, persist

for years, or be permanent. The affected extremity usually appears normal, unless there has been tissue necrosis, which is uncommon. Affected extremities are cool and are often very sensitive to cold. Chronic pain, usually in response to cold, and hyperhidrosis are common. (See '[Complications of nonfreezing cold injury](#)' above.)

NFCI is a clinical diagnosis; no specific imaging or laboratory studies are useful for establishing the diagnosis, and such studies are generally unnecessary to manage routine cases.

- **Differential diagnosis** – The differential diagnosis for water immersion injuries includes frostbite, pressure-induced soft tissue injury (which may coexist with immersion injury), and soft tissue infection. (See '[Differential diagnosis of nonfreezing cold injury](#)' above and '[Differential diagnosis of warm water immersion injury](#)' above.)
- **Treatment** – Key elements in the treatment of NFCI are summarized below; details are provided in the text:
 - If present, treat systemic hypothermia before treating local cold injury. Examine the patient closely for other conditions and injuries. Assess extremities for frostbite and treat as necessary. (See "[Accidental hypothermia in adults](#)", section on '[Management](#)' and "[Frostbite: Emergency care and prevention](#)".)
 - Do not actively rewarm extremities with isolated NFCI. Rapid rewarming increases pain and edema. Extremities with NFCI should be allowed to rewarm gradually with bed rest, elevation of the legs or hands, and air-drying at room temperature.
 - Replace fluid losses, which may be substantial. Use isotonic intravenous fluids warmed to 42°C to rehydrate and help prevent hypothermia.
 - Give tetanus prophylaxis. Do not give prophylactic treatment for other infections or for pain.
 - Nonsteroidal antiinflammatory drugs (NSAIDs) and opioids may be administered initially for pain relief but are usually not effective. We suggest treating pain as soon as it begins with [amitriptyline](#) (50 to 100 mg orally at bedtime) (**Grade 2C**). Higher doses can be given for breakthrough pain. If amitriptyline is not effective, neuropathic pain medications such as [gabapentin](#) can be administered.
 - Obtain immediate surgical consultation for any sign of possible tissue necrosis, such as hemorrhagic blistering.

Warm water immersion injuries generally heal without need of significant medical interventions. (See ['Management of warm water immersion injury'](#) above.)

- **Prevention** – Tips for preventing water immersion injuries are provided in the text. (See ['Prevention of nonfreezing cold injury'](#) above and ['Prevention of warm water immersion injury'](#) above.)

REFERENCES

1. Smith JL, Ritchie J, Dawson J. On the pathology of trench-frostbite. *Lancet* 1915; 2:595.
2. Francis TJ. [Non freezing cold injury: a historical review.](#) *J R Nav Med Serv* 1984; 70:134.
3. White JC. Vascular and neurologic lesions in survivors of shipwreck. *N Engl J Med* 1943; 28:211.
4. Adnot J, Lewis CW. Immersion foot syndromes. In: *Military Dermatology*, James WD (Ed), Borden Institute, Washington, DC 1994. p.55.
5. Ungley CC, Channell GD, Richards RL. The immersion foot syndrome. *Br J Surg* 1946; 33:17.
6. [Laden GD, Purdy G, O'Rielly G. Cold injury to a diver's hand after a 90-min dive in 6 degrees C water.](#) *Aviat Space Environ Med* 2007; 78:523.
7. Knight BW. "Trench foot" in civilians. *Br Med J* 1940; 1.
8. Buckels LJ, Gill KA Jr, Anderson GT. Warm water immersion foot. *Res Rep US Nav Med Field Res Lab* 1967; 17:1.
9. [Paddy-field foot.](#) *Lancet* 1967; 1:1043.
10. [Allen AM, Taplin D. Tropical immersion foot.](#) *Lancet* 1973; 2:1185.
11. [Forbes KE, Foster P. An unusual case of an immersion hand presentation in a military signaller operating in the jungle in Belize.](#) *J R Army Med Corps* 2017; 163:422.
12. [Humphrey W, Ellyson R. Warm water immersion foot: still a threat to the soldier.](#) *Mil Med* 1997; 162:610.
13. [Haller JS Jr. Trench foot--a study in military-medical responsiveness in the Great War, 1914-1918.](#) *West J Med* 1990; 152:729.
14. Wayne TF, DeBakey ME.. *Cold Injury, Ground Type*, Office of the Surgeon General Department of the Army, Washington, DC 1958.
15. Thomas JR, Oakley HN. Nonfreezing cold injury. In: *Medical Aspects of Harsh Environments*, Pandolf KB, Burr RE (Eds), Washington, DC 2001. p.467.
16. [Webster DR, Bigelow WG. Injuries Due to Cold, Frostbite, Immersion Foot and](#)

Hypothermia. *Can Med Assoc J* 1952; 67:534.

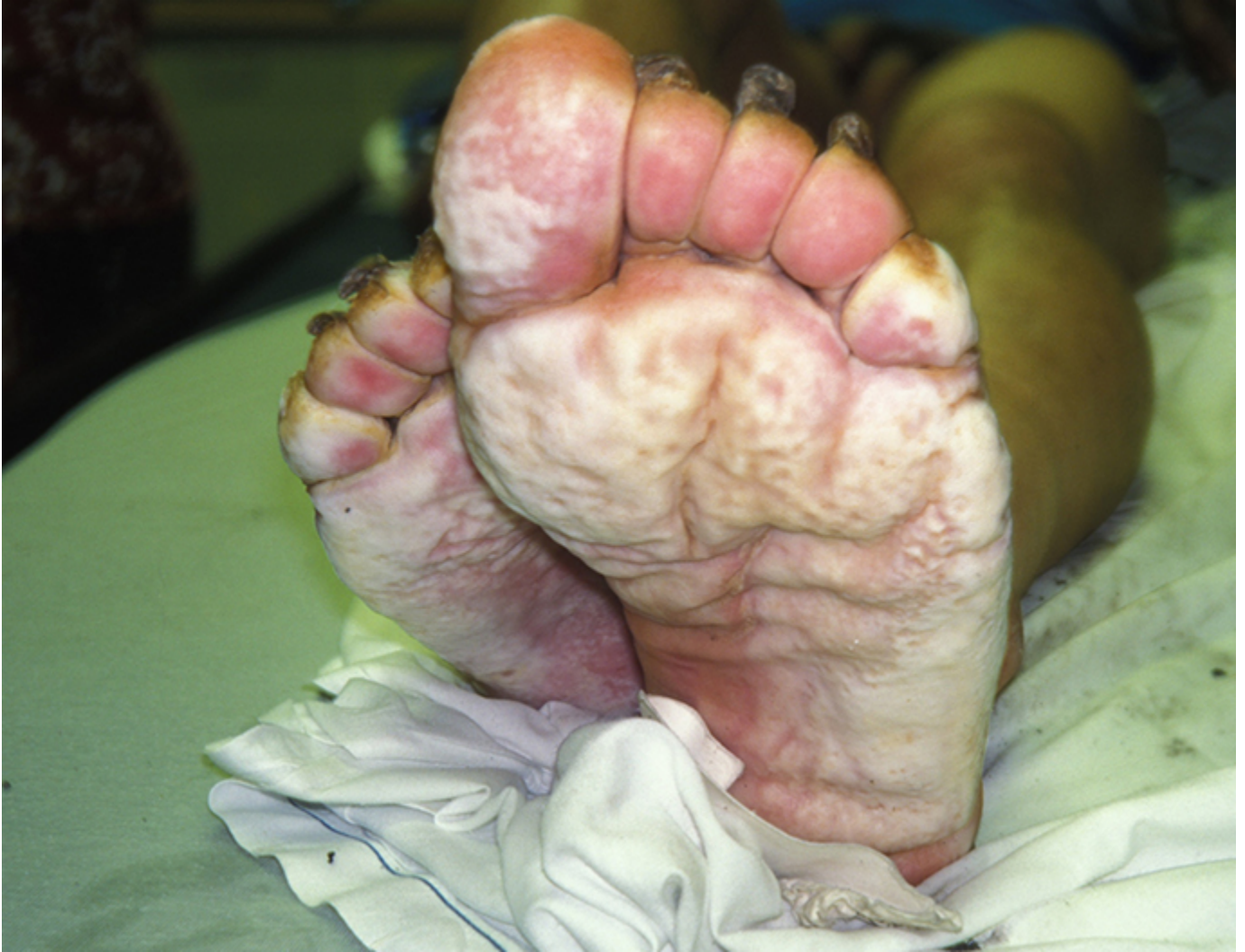17. GREENFIELD AD, SHEPHERD JT, WHELAN RF. Cold vasoconstriction and vasodilatation. *Ir J Med Sci* 1951; :415.
18. Daanen HA, van der Struijs NR. Resistance Index of Frostbite as a predictor of cold injury in arctic operations. *Aviat Space Environ Med* 2005; 76:1119.
19. Collier T, Patel A, Rinaldi R. Hypothermia-induced peripheral polyneuropathy after an episode of drowning. *PM R* 2012; 4:230.
20. Løseth S, Bågenholm A, Torbergsen T, Stålberg E. Peripheral neuropathy caused by severe hypothermia. *Clin Neurophysiol* 2013; 124:1019.
21. MONTGOMERY H. Experimental immersion foot; review of the physiopathology. *Physiol Rev* 1954; 34:127.
22. Kuht JA, Woods D, Hollis S. Case series of non-freezing cold injury: epidemiology and risk factors. *J R Army Med Corps* 2019; 165:400.
23. Kuht JA, Woods D, Hollis S. Case series of non-freezing cold injury: the modern clinical syndrome. *BMJ Mil Health* 2020; 166:324.
24. Webster DR, Woolhouse FM, Johnston JL. Immersion foot. *J Bone Joint Surg Am* 1942; 24: 785.
25. Wrenn K. Immersion foot. A problem of the homeless in the 1990s. *Arch Intern Med* 1991; 151:785.
26. Aldington DJ, McQuay HJ, Moore RA. End-to-end military pain management. *Philos Trans R Soc Lond B Biol Sci* 2011; 366:268.
27. McGreevy K, Bottros MM, Raja SN. Preventing Chronic Pain following Acute Pain: Risk Factors, Preventive Strategies, and their Efficacy. *Eur J Pain Suppl* 2011; 5:365.
28. Ionescu AM, Hutchinson S, Ahmad M, Imray C. Potential new treatment for non-freezing cold injury: is Iloprost the way forward? *J R Army Med Corps* 2017; 163:361.
29. Mills W. Clinical Aspects of Freezing Cold Injuries. In: *Medical Aspects of Harsh Environments*, Pandolf K, Burr R (Eds), Office of the Surgeon General, Falls Church, VA 2001. Vol 1, p.429.
30. Vale TA, Symmonds M, Polydefkis M, et al. Chronic non-freezing cold injury results in neuropathic pain due to a sensory neuropathy. *Brain* 2017; 140:2557.
31. Anand P, Privitera R, Yiangou Y, et al. Trench Foot or Non-Freezing Cold Injury As a Painful Vaso-Neuropathy: Clinical and Skin Biopsy Assessments. *Front Neurol* 2017; 8:514.

32. Jørum E, Opstad PK. A 4-year follow-up of non-freezing cold injury with cold allodynia and neuropathy in 26 naval soldiers. *Scand J Pain* 2019; 19:441.
33. Buckels LJ, Gill KA Jr, Anderson GT. Prophylaxis of warm-water-immersion foot. *JAMA* 1967; 200:681.
34. Taplin D, Zaias N, Blank H. The role of temperature in tropical immersion foot syndrome. *JAMA* 1967; 202:546.
35. Douglas JS Jr, Eby CS. Silicone for immersion foot prophylaxis: where and how much to use. *Mil Med* 1972; 137:386.

This generalized information is a limited summary of diagnosis, treatment, and/or medication information. It is not meant to be comprehensive and should be used as a tool to help the user understand and/or assess potential diagnostic and treatment options. It does NOT include all information about conditions, treatments, medications, side effects, or risks that may apply to a specific patient. It is not intended to be medical advice or a substitute for the medical advice, diagnosis, or treatment of a health care provider based on the health care provider's examination and assessment of a patient's specific and unique circumstances. Patients must speak with a health care provider for complete information about their health, medical questions, and treatment options, including any risks or benefits regarding use of medications. This information does not endorse any treatments or medications as safe, effective, or approved for treating a specific patient. UpToDate, Inc. and its affiliates disclaim any warranty or liability relating to this information or the use thereof. The use of this information is governed by the Terms of Use, available at <https://www.wolterskluwer.com/en/know/clinical-effectiveness-terms>
©2023 UpToDate, Inc. and its affiliates and/or licensors. All rights reserved.

GRAPHICS

Nonfreezing cold injury ("trench foot" or "immersion foot")

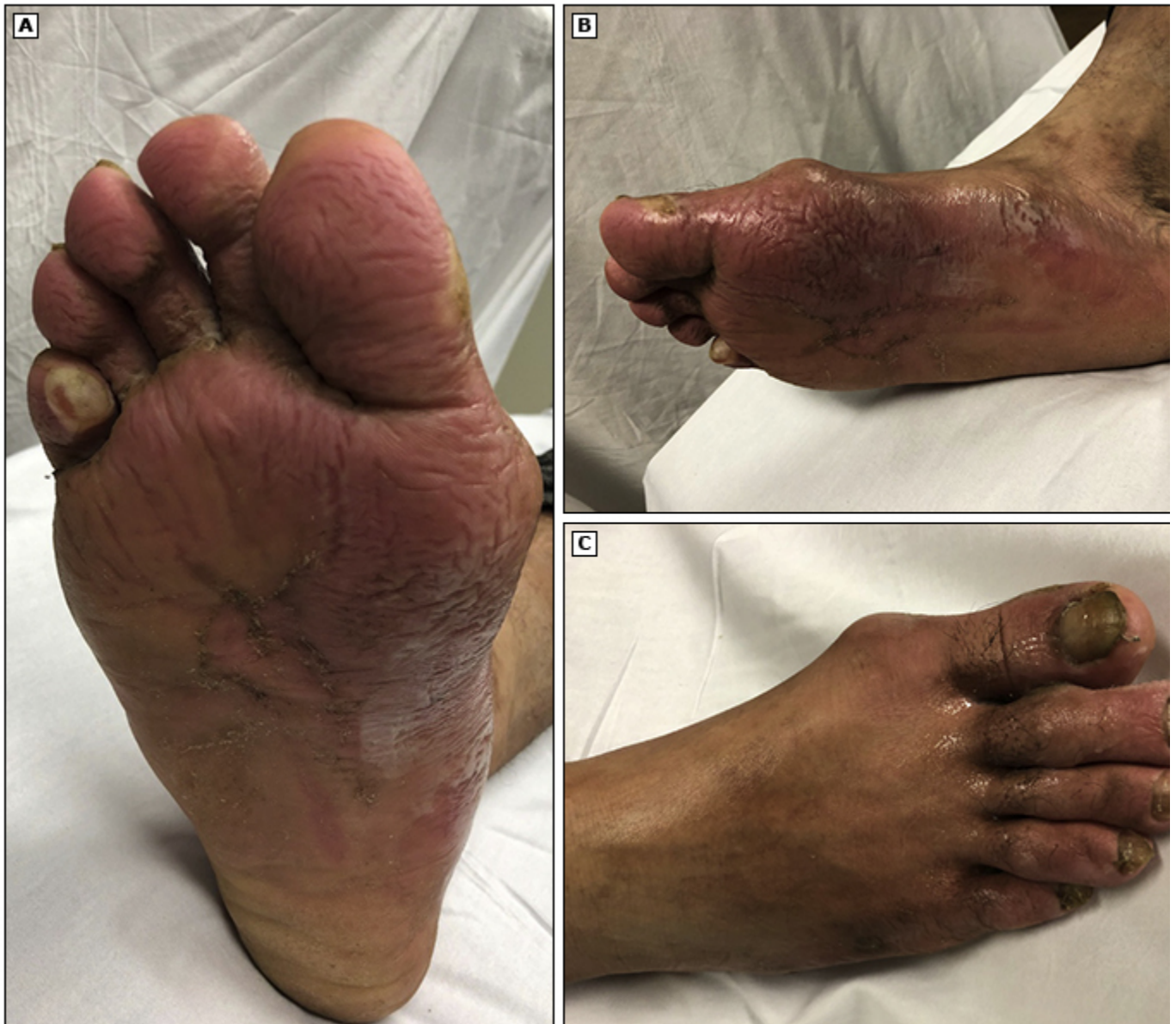

The photo above shows nonfreezing cold injury ("trench foot" or "immersion foot") in a homeless man seen in an emergency department after he was found intoxicated outdoors with wet shoes and

Courtesy of Ken Zafren, MD.

Graphic 101027 Version 1.0

Mild case of tropical immersion foot



The photographs above are taken of a patient with a mild case of tropical immersion foot. The exposure occurred in a temperate environment with temperatures ranging from about 15 to 26.5°C (60 to 80°F).

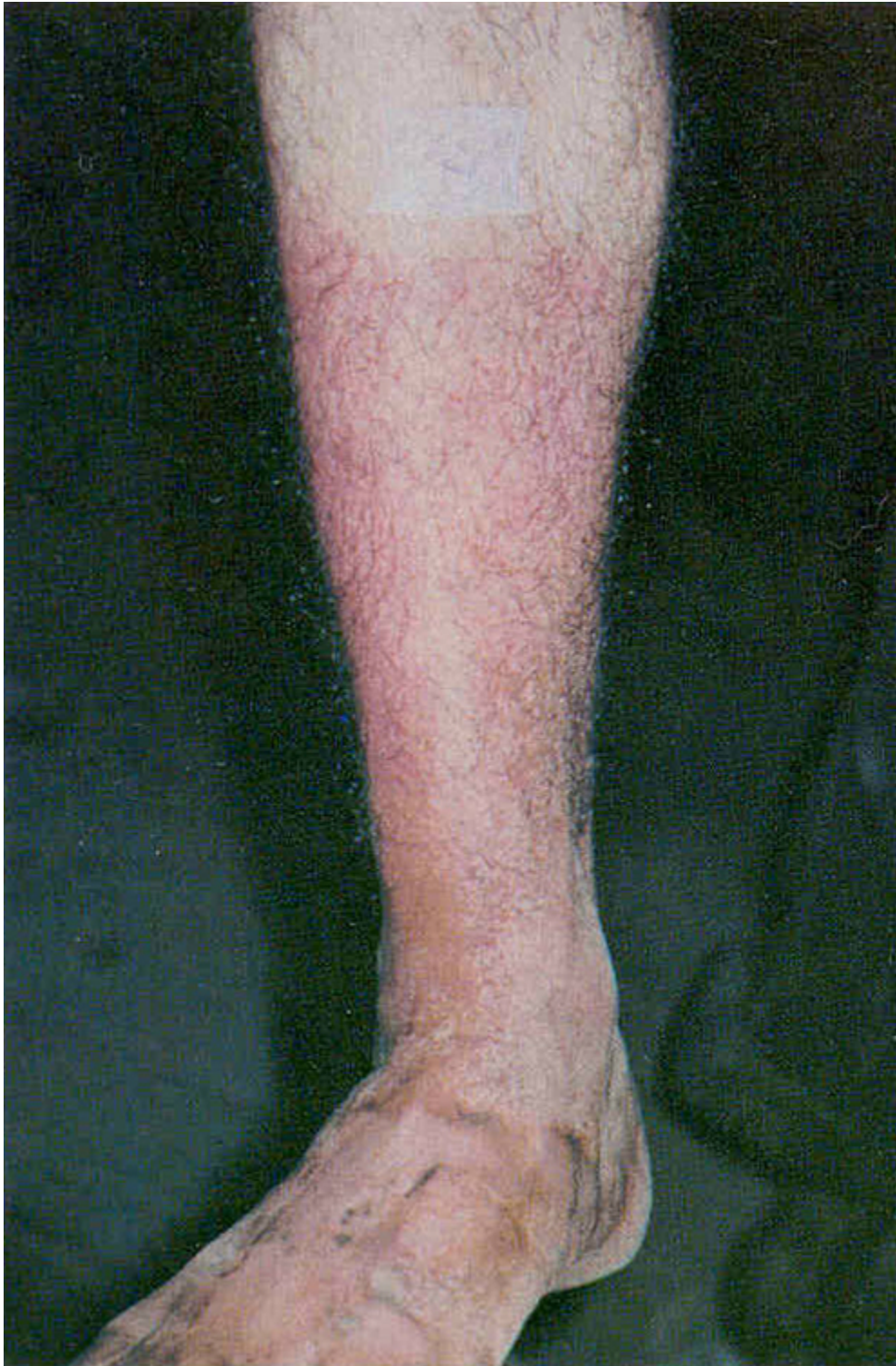(A) Plantar right foot

(B) Medial right foot

(C) Dorsal right foot

From: McCormack N, Bitter CC. My feet are killing me: a hiker's journey. Wilderness Environ Med. 2020 [Epub ahead of print]. Reprinted with permission from the Wilderness Medical Society. ©2020 Wilderness Medical Society.

Early tropical immersion foot

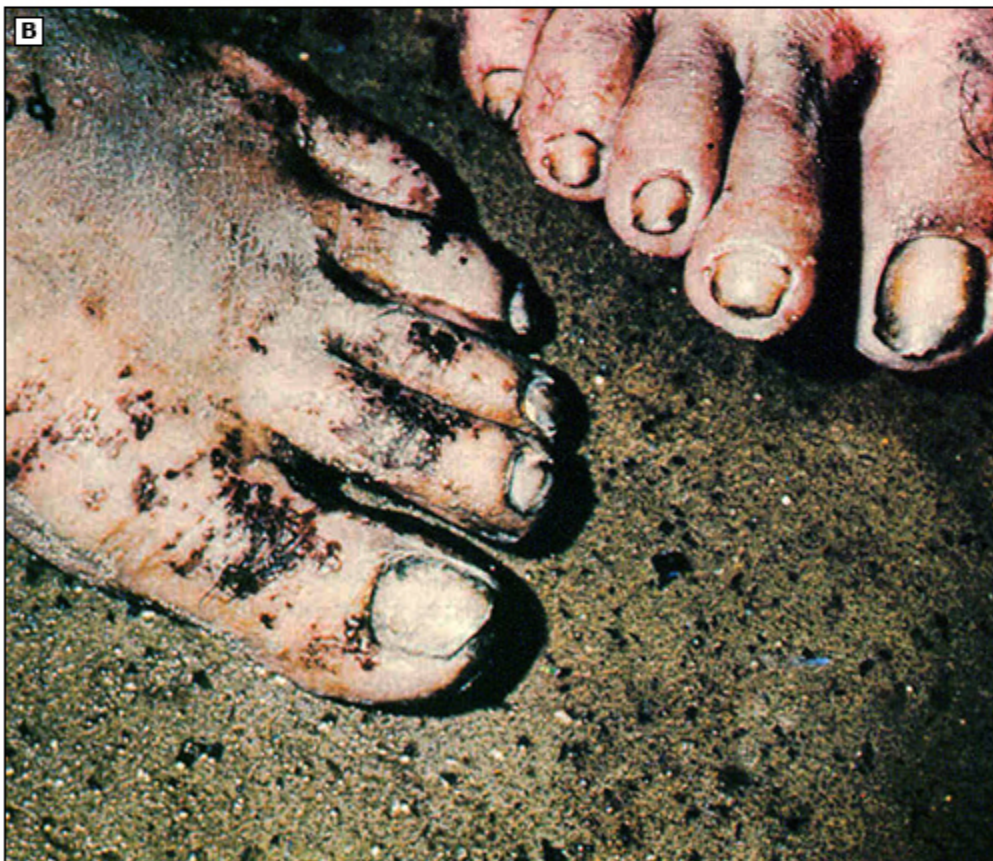
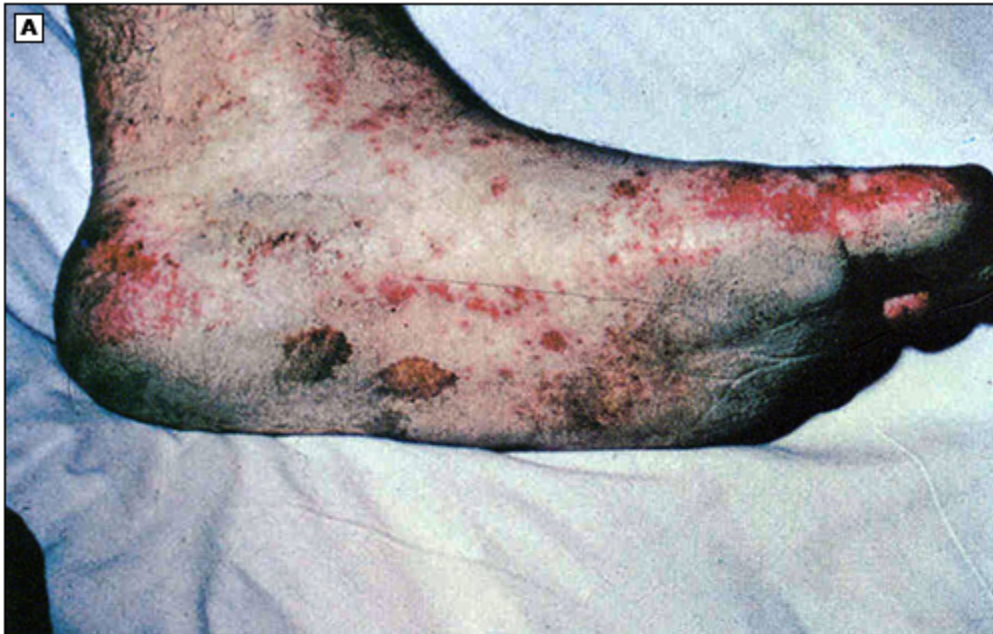
An early, mild case of tropical immersion foot showing intense erythema and a line of demarcation at boot top level. Pitting edema of the ankles and dorsa of the feet was present in more severe cases.

Available at: <https://achh.army.mil/history/book-vietnam-skindiseases-chapter6> (Accessed on July 25, 2022).

Graphic 116521 Version 2.0

Tropical immersion foot with ecchymotic blotches



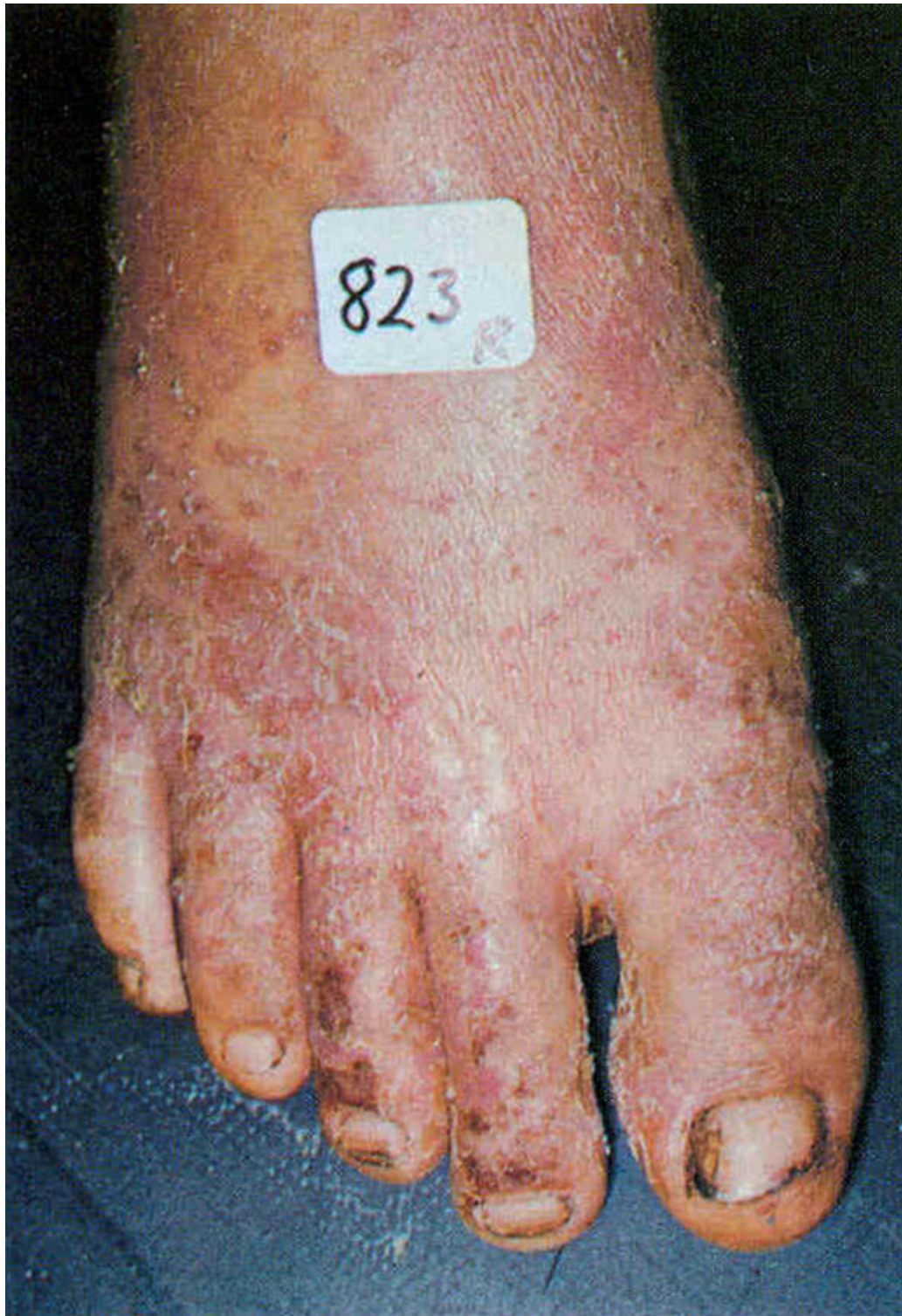(A) Tropical immersion foot in an American soldier showing diffuse ecchymotic blotches.

(B) Later stage of the same phenomenon.

1965-1972. US Army Medical Department - Office of Medical History, Washington 1977.
Available at: <https://achh.army.mil/history/book-vietnam-skindiseases-chapter6> (Accessed on July 25, 2022).

Graphic 116523 Version 3.0

Tropical immersion foot post-hospitalization



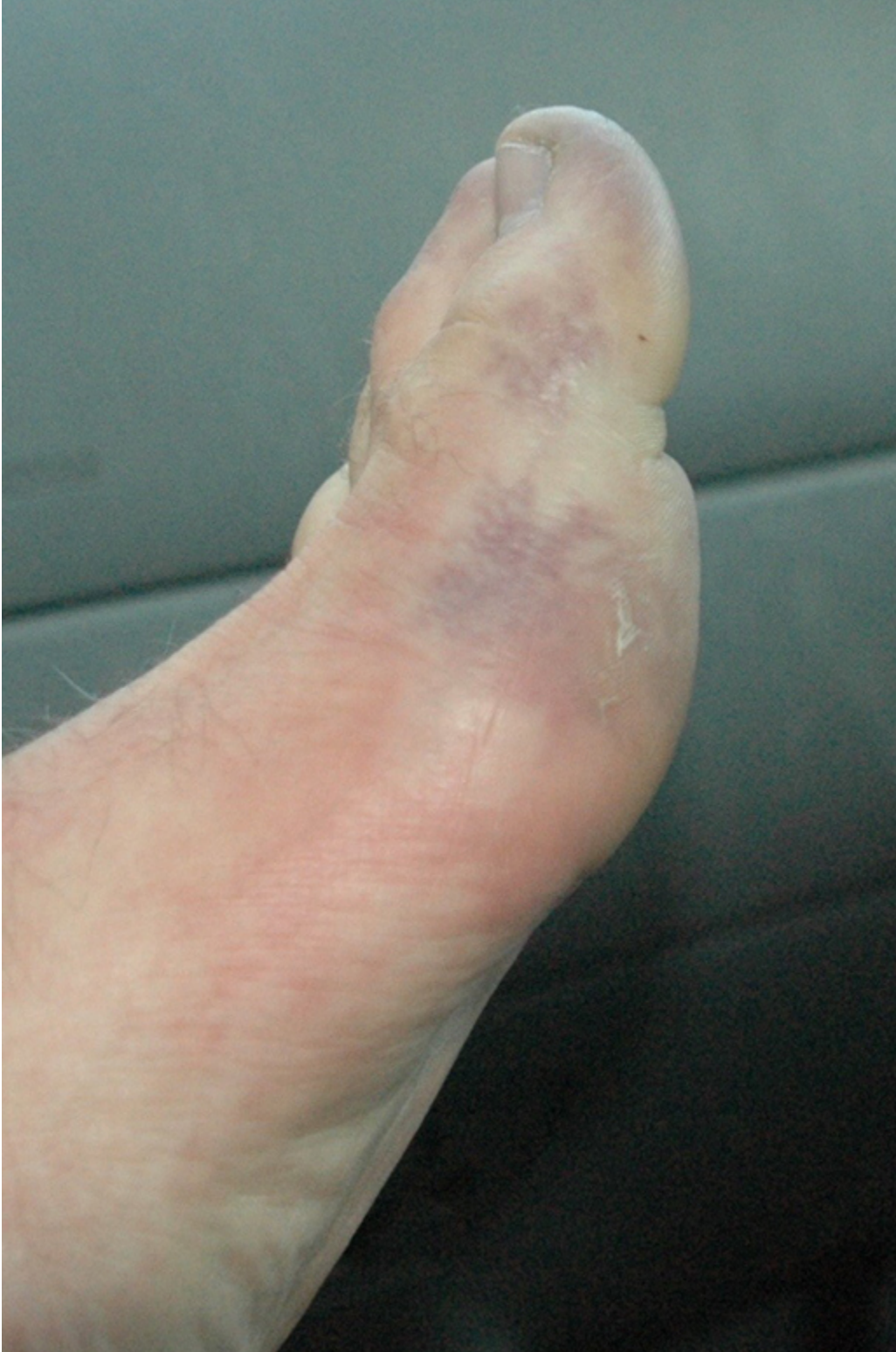Tropical immersion foot four days post-hospitalization. Note edema, blotchy discoloration, and desquamation of the epidermis from the dorsum.

Reproduced from: Allen A. *Internal Medicine in Vietnam, Volume I: Skin Diseases in Vietnam, 1965-1972*. US Army Medical Department - Office of Medical History, Washington 1977. Available at: <https://achh.army.mil/history/book-vietnam-skindiseases-chapter6> (Accessed on July 25,

2022).

Graphic 116522 Version 2.0

Frostbite of the foot prior to thawing

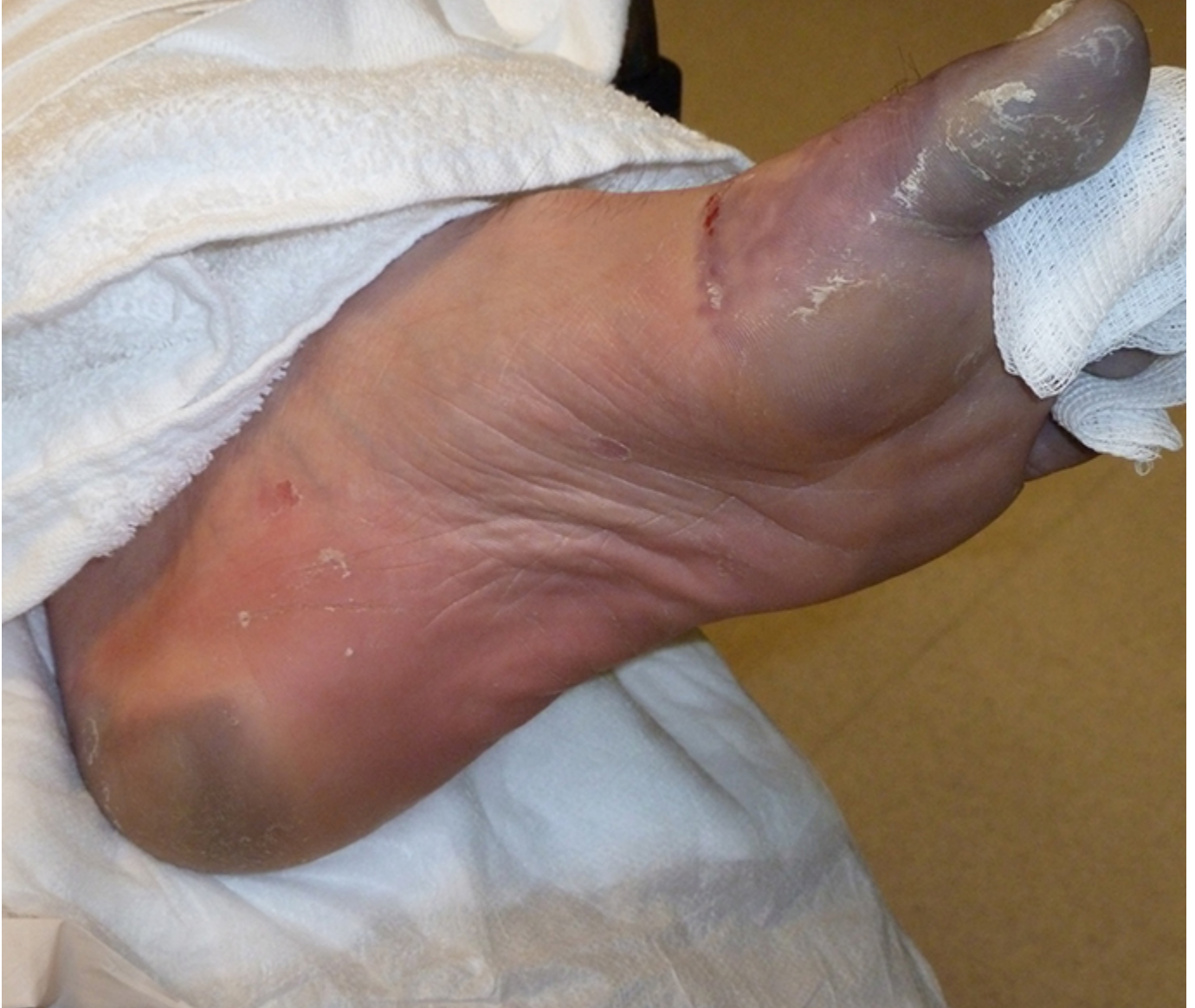

The photo above shows frostbite of the foot at first presentation. Prior to thawing, it is impossible to distinguish mild frostbite from severe.

Courtesy of Nicholas Kanaan, MD.

Graphic 101058 Version 1.0

Early demarcation of severe frostbite of the foot

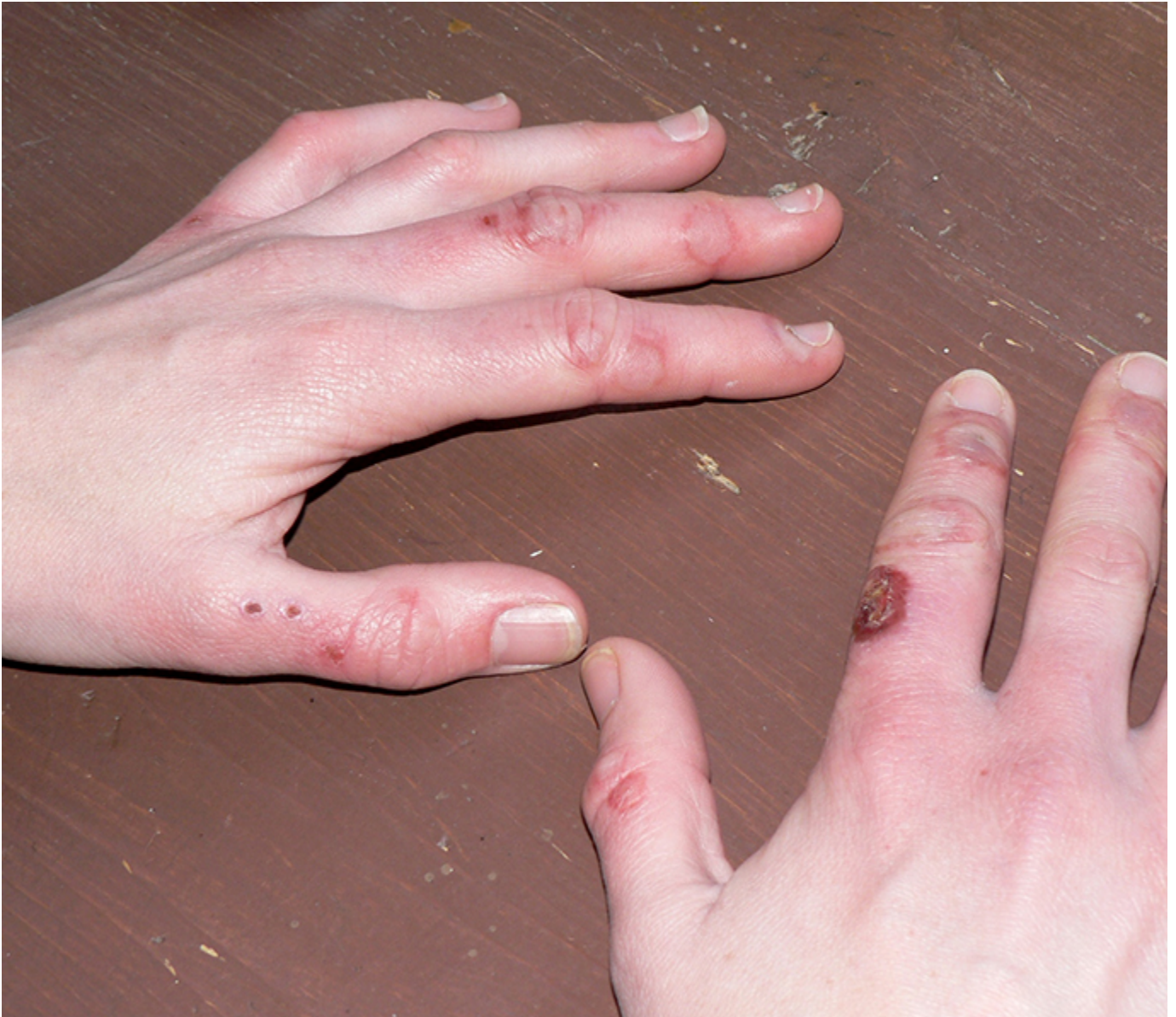

The photo above shows early demarcation of severe frostbite of the foot. The violaceous hue and lack of are grave prognostic signs.

Courtesy of Ken Zafren, MD.

Graphic 101025 Version 1.0

Pernio in a woman chronically exposed to dry cold

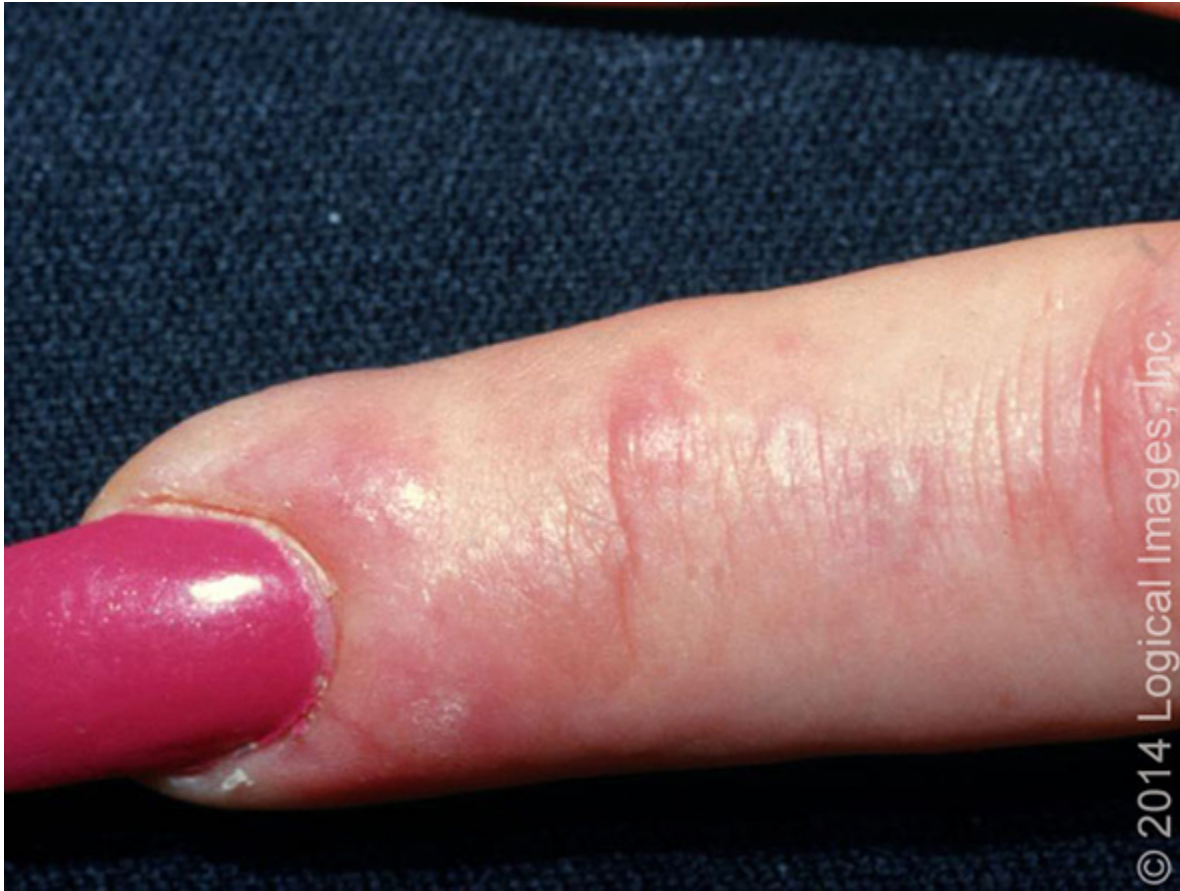

The photo above shows pernio in a woman chronically exposed to dry cold in an austere environment. Pernio is a common condition.

Courtesy of Alice F Murray, MD.

Graphic 101018 Version 2.0

Pernio

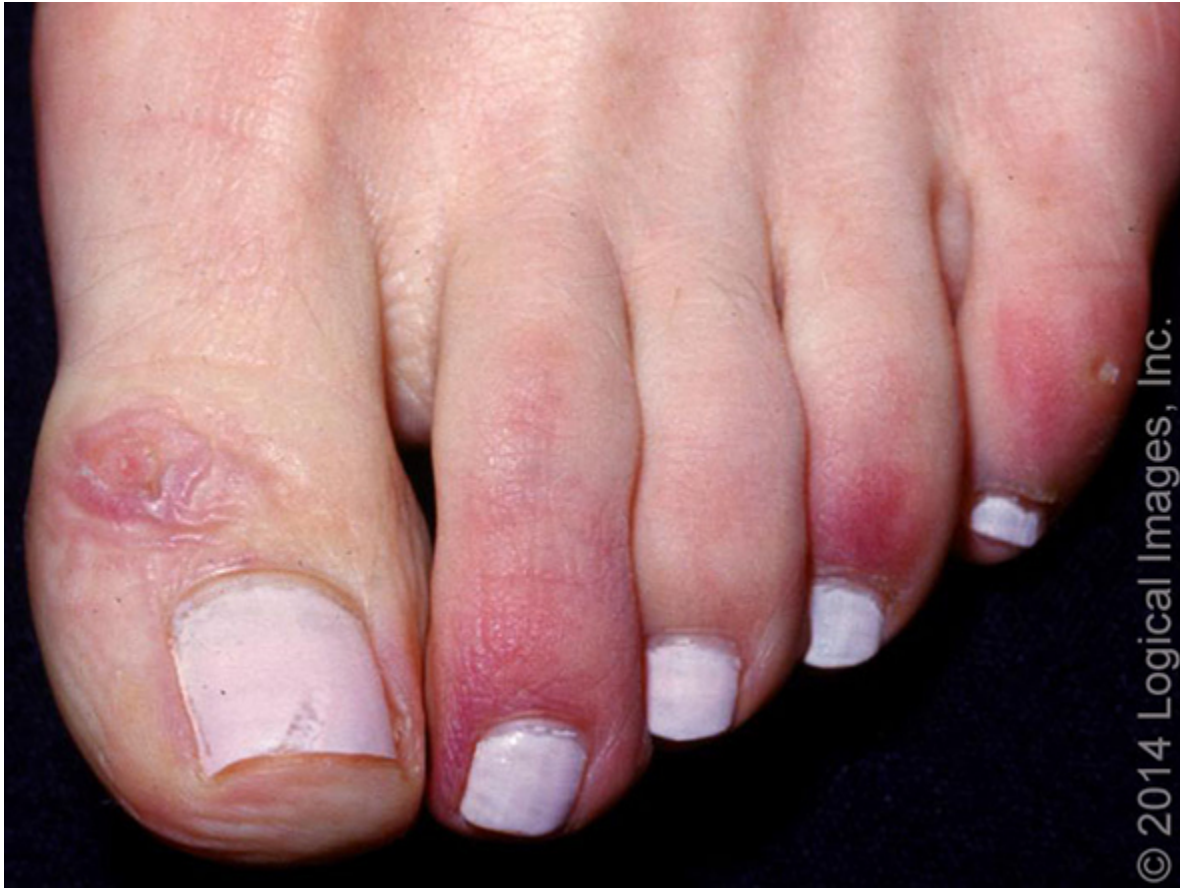

Edematous, erythematous to violaceous papules and papulovesicles on the finger of a patient with pernio.

Reproduced with permission from: www.visualdx.com. Copyright VisualDx. All rights reserved.

Graphic 94187 Version 2.0

Pernio

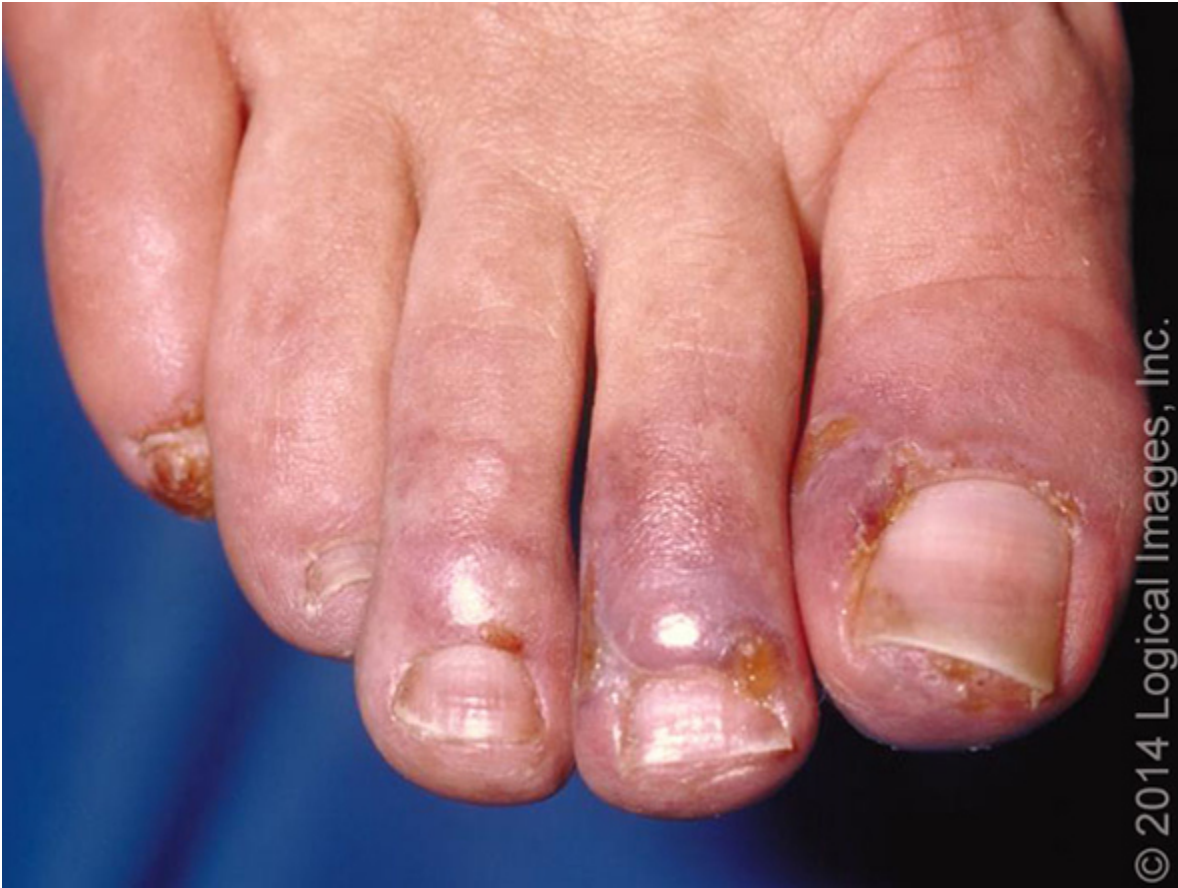

Erythematous to violaceous edematous macules and papules on the toes.

Reproduced with permission from: www.visualdx.com. Copyright VisualDx. All rights reserved.

Graphic 94183 Version 2.0

Pernio



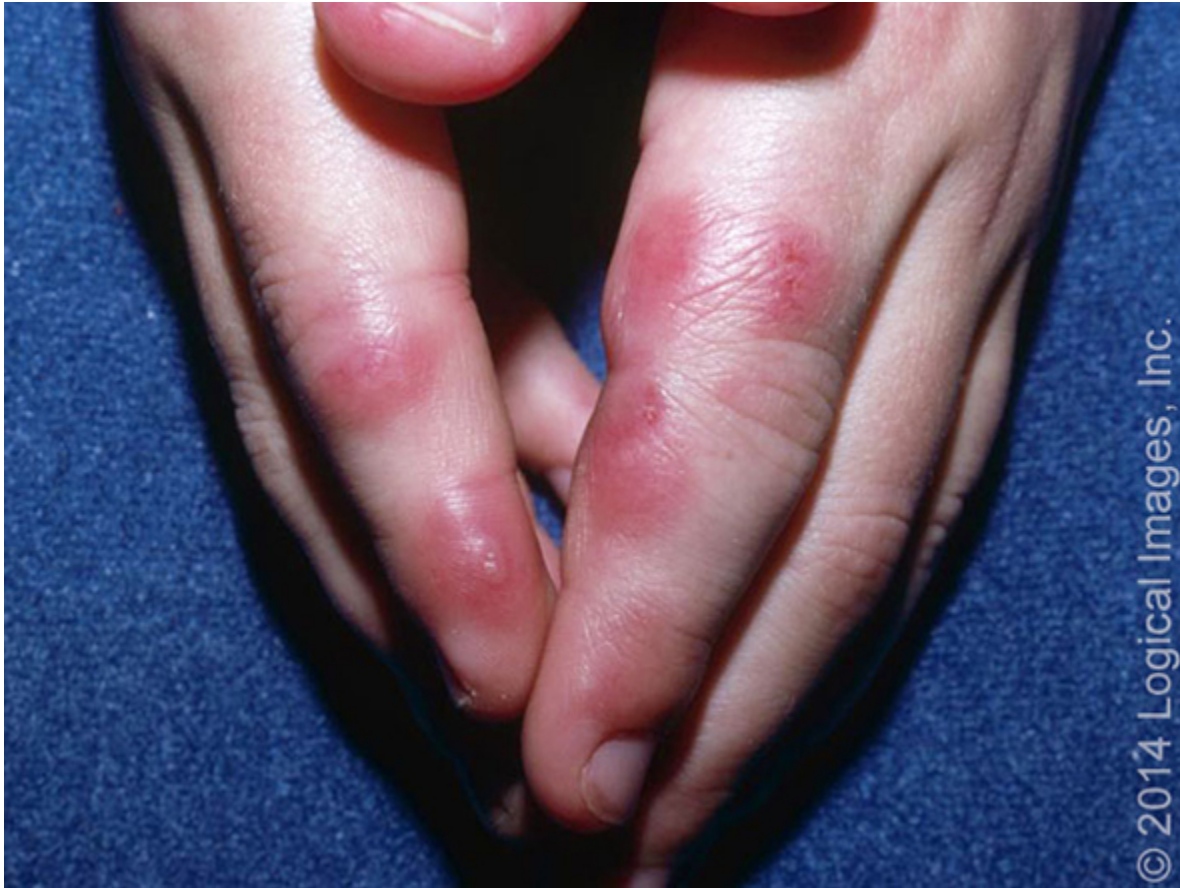© 2014 Logical Images, Inc.

Violaceous edematous papules and ulceration on the toes.

Reproduced with permission from: www.visualdx.com. Copyright VisualDx. All rights reserved.

Graphic 94186 Version 2.0

Pernio

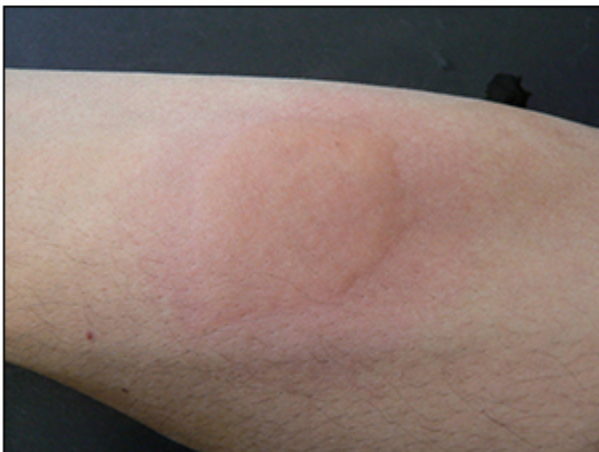

Erythematous to violaceous papules and plaques with blistering in a child with pernio.

Reproduced with permission from: www.visualdx.com. Copyright VisualDx. All rights reserved.

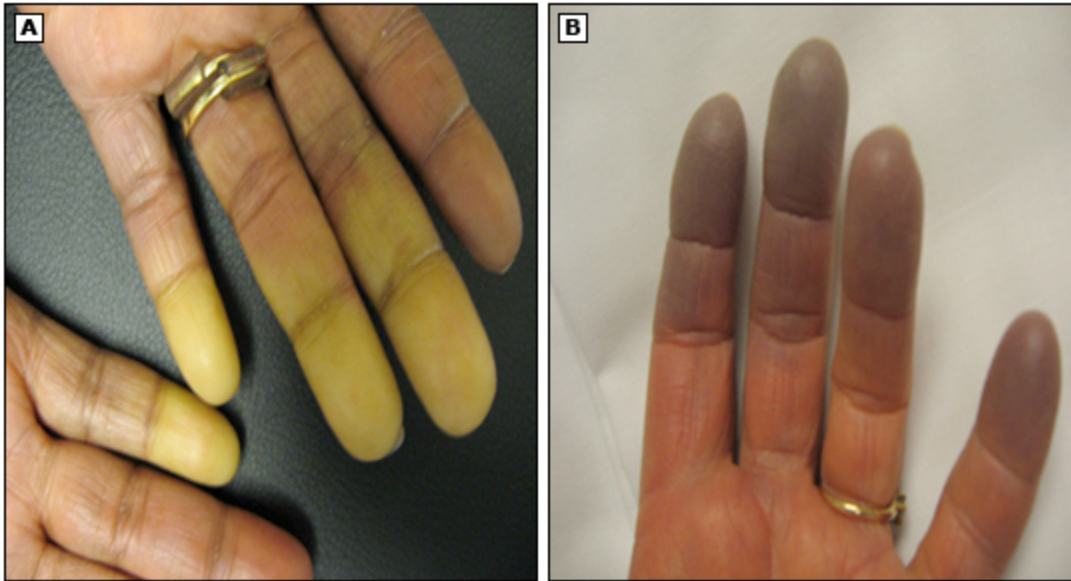
Graphic 94185 Version 2.0

Ice cube test for cold urticaria



This series of photographs illustrates a positive ice cube test in a patient with cold urticaria. A plastic bag containing an ice cube and a small amount of water is applied to the volar aspect of the patient's forearm for 5 minutes and then removed. The area of application is observed and the response is recorded 10 minutes after removal. It is preferable to use a bag with ice and water rather than applying an ice cube directly to the skin, since some patients can sustain skin damage at temperatures below 0°C. Refer to the UpToDate topic on cold urticaria for further discussion of this test and its interpretation.

Raynaud phenomenon



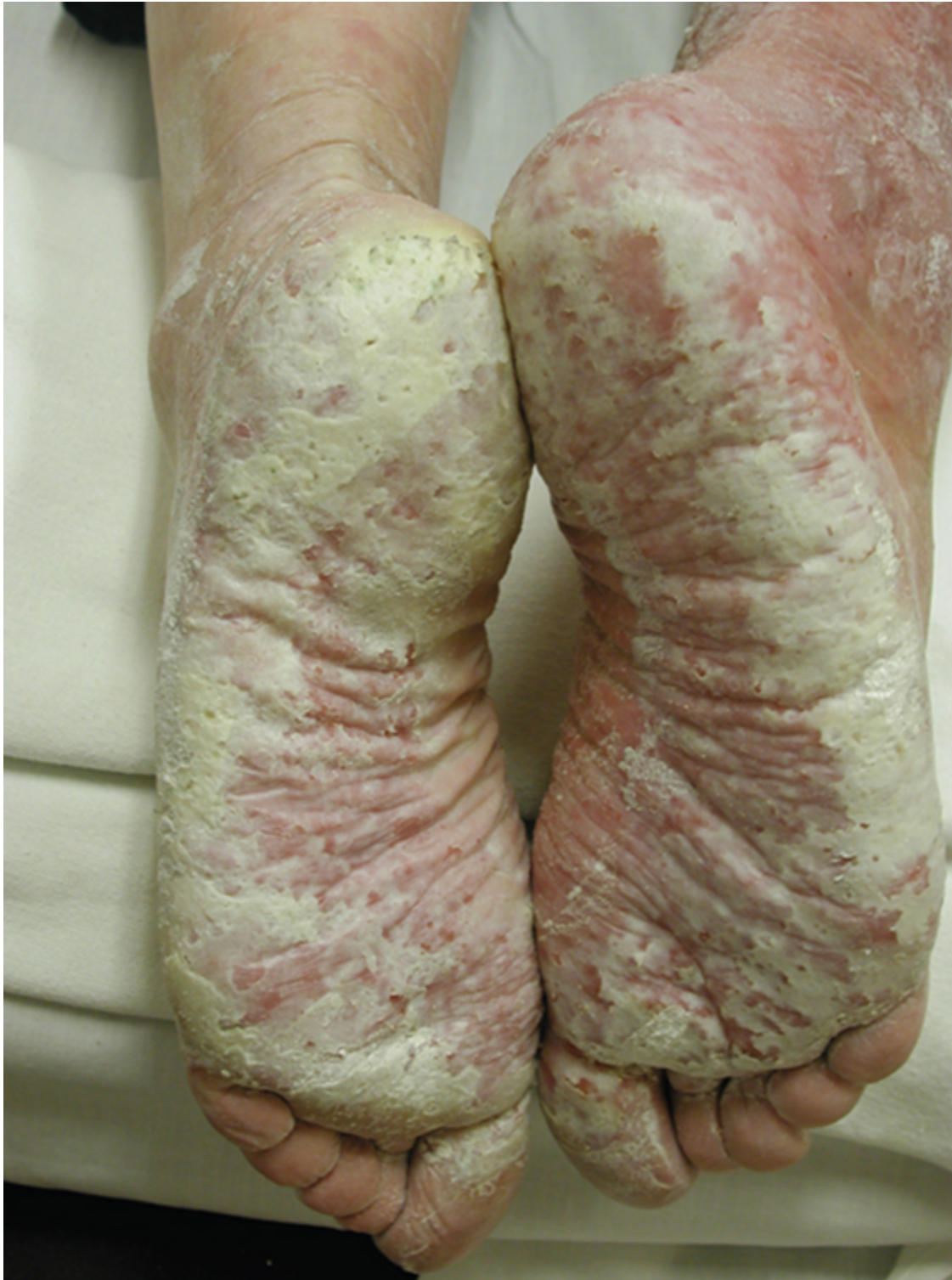(Panel A) Sharply demarcated pallor in several fingers resulting from the closure of digital arteries.

(Panel B) Digital cyanosis of the fingertips resulting from vasoconstriction in the thermoregulatory vessels in the skin.

Courtesy of Fredrick M Wigley, MD.

Graphic 66438 Version 9.0

Severe trench foot in an early stage



This unfortunate homeless patient suffered prolonged exposure to a cold wet environment with resulting severe trench foot.

Reproduced with permission from: Zafren K, Thurman RJ, Jones ID. Environmental Conditions. In: The Atlas of Emergency Medicine, 4th ed, Knoop KJ, Stack LB, Storrow AB, Thurman RJ (Eds), McGraw-Hill Education, 2016. Copyright © 2016 McGraw-Hill Education. McGraw-Hill Education makes no

representations or warranties as to the accuracy of any information contained in the McGraw-Hill Education Material, including any warranties of merchantability or fitness for a particular purpose. In no event shall McGraw-Hill Education have any liability to any party for special, incidental, tort, or consequential damages arising out of or in connection with the McGraw-Hill Education Material, even if McGraw-Hill Education has been advised of the possibility of such damages.

Graphic 116323 Version 2.0

Contributor Disclosures

Ken Zafren, MD, FAAEM, FACEP, FAWM No relevant financial relationship(s) with ineligible companies to disclose. **Daniel F Danzl, MD** No relevant financial relationship(s) with ineligible companies to disclose. **Michael Ganetsky, MD** No relevant financial relationship(s) with ineligible companies to disclose.

Contributor disclosures are reviewed for conflicts of interest by the editorial group. When found, these are addressed by vetting through a multi-level review process, and through requirements for references to be provided to support the content. Appropriately referenced content is required of all authors and must conform to UpToDate standards of evidence.

[Conflict of interest policy](#)

→